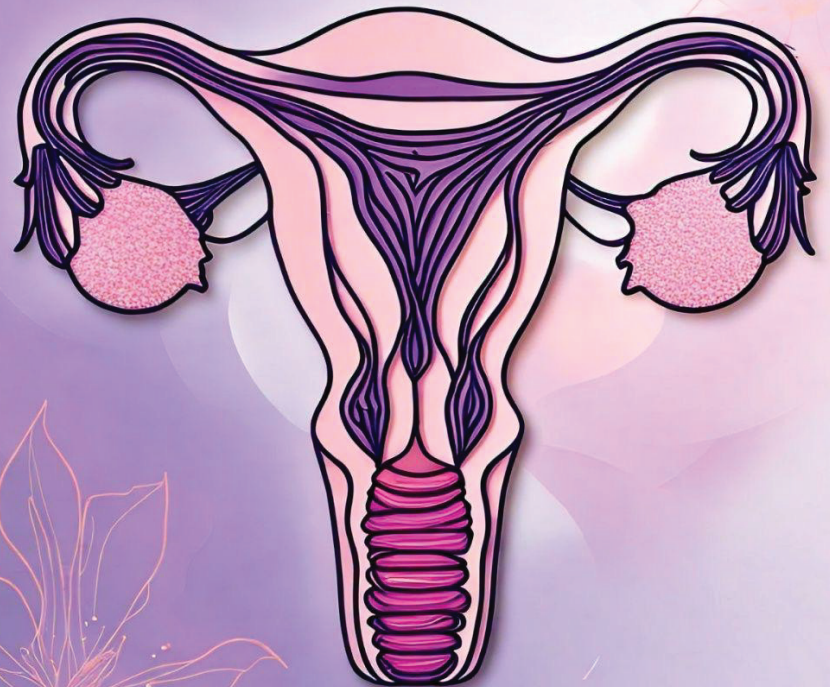




Vol. 1 | Issue- 1 | Sept 2024

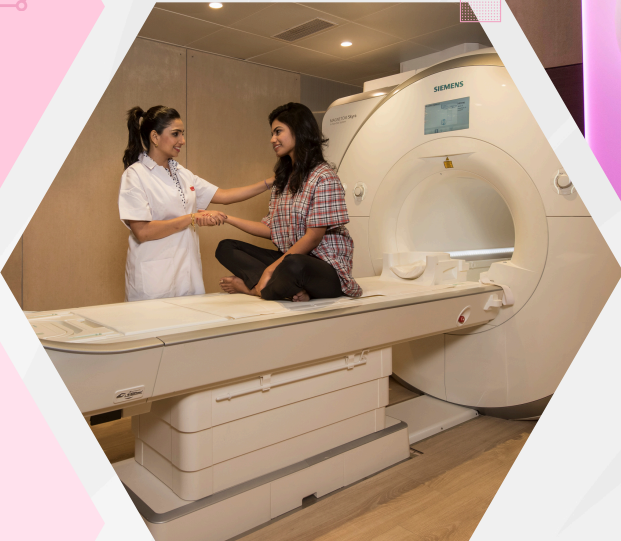

# MOGS Chronicles

A Compilation of Interesting Cases

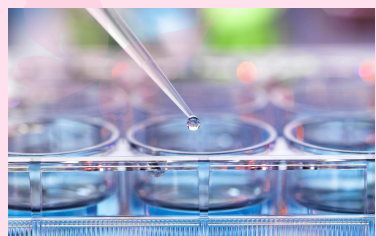Editor-in-Chief: **Suvarna Khadilkar**

Official publication of Mumbai Obstetric and Gynaecological Society for internal circulation

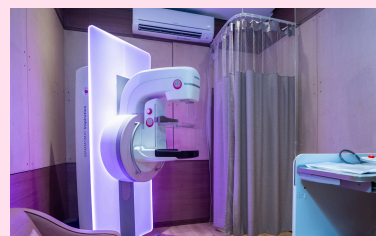

## Where **Trust** Meets **Expertise** in Women's Health

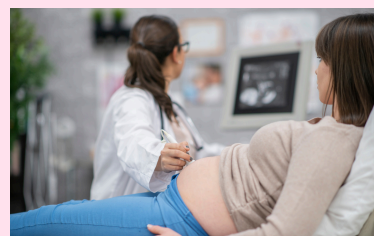Every woman deserves care that is personalized, private, and fast. At EVA Health, we provide world-class diagnostics and health checkups exclusively for women, where comfort and expertise come together.



GENETIC TESTING  
(INCLUDING NIPT)



TOTAL BREAST CARE



PREGNANCY CARE



LAB INVESTIGATIONS

## Healthcare Designed **Exclusively** for Women

✓  
Minimal waiting

✓  
Complete privacy

✓  
All Women Staff



+91 9324909383  
INFO@NMEVAHEALTH.COM  
WWW.NMEVAHEALTH.COM



**MUMBAI:** MARINE LINES |  
KHAR | MULUND  
**PUNE:** KALYANI NAGAR  
**BENGALURU:** DOMLUR



@NMEVAHEALTH



NM EVA HEALTH

# MOGS Chronicles

Official publication of The Mumbai Obstetric and Gynaecological Society



## EDITORIAL BOARD

### EDITOR-IN-CHIEF

Dr Suvarna Khadilkar  
President MOGS

### ASSOCIATE EDITOR

Dr Geetha Balsarkar  
Secretary MOGS

### JOINT ASSOCIATE EDITORS:

Dr. Rajendra Sankpal  
Vice – President

Dr. Shailesh Kore  
Vice – President

Dr. Kedar Ganla  
Jt. Secretary

### EXECUTIVE EDITOR

Dr Riddhi Desai

### MANAGING COMMITTEE MEMBERS

---

Dr. Reena Wani

Dr. Priya Vora

Dr. Rohan Palshetkar

Dr. Pradnya Supe

Dr. Sudha Tandon

Dr. Punit Bhojani

Dr. Bhumika Kotecha  
Mundhe

Dr. Pradnya Changede

Dr. Atul Ganatra

Dr. Madhuri Mehendale

Dr. Siddesh Iyer

Dr. Riddhi Desai

Dr. Ganpat Sawant

Dr. Komal Chavan

Dr. Gaurav Desai

Dr. Gautam Sonawane

Dr. Priti Samir Vyas

Dr. Mansi Medhekar

Dr. Shreya Prabhoo

Dr. Pratik Tambe

Dr. Raju Sahetya

### PAST PRESIDENTS

Dr. Anahita Chauhan (Immediate)

Dr. Jaydeep Tank

Dr. Rishma Dhillon Pai

Dr. Sarita Bhalerao

Dr. Niranjan Chavan

### CO-OPTED MEMBERS

Dr. Mandakini Megh

Dr. Tushar Palve

Dr. Vijaya Babre



**Dear Esteemed Colleagues,**

It is with great pleasure that we present to you the first edition of the MOGS Chronicles, a compilation of intriguing and educational case reports from our dedicated members. I always felt the need for exchanging our case management skills with peers so that they learn from each other. In the past I have been editor in chief of the most prestigious journal of India JOGI, FOGSI. I observed that case reports are of low priority for publication hence the idea to launch this publication, dedicated exclusively to case reports, was conceived.

The cases featured in this edition are a testament to the exceptional clinical acumen and innovative problem-solving skills of our members. Each report provides valuable insights into rare and unusual presentations, diagnostic challenges, and unique management strategies that can enhance our clinical practice and improve patient outcomes.

As medical professionals, we understand the profound impact that mentorship and shared experiences can have on our growth and development. The MOGS Chronicles serves as a platform for our junior colleagues to learn the art of medical writing. It also will enhance the skills and help practitioners follow the best practices in their day-to-day patient management. It is my dream to see this initiative transform into an indexed journal of MOGS.

We extend our heartfelt gratitude to all contributors for their meticulous efforts in documenting and sharing these cases. We also thank our reviewers and editorial team for their invaluable contributions in ensuring the quality and relevance of this.

I will fail in my duty if I don't acknowledge the hard work put in by my executive editor, Dr Riddhi Desai, supported by entire editorial board.

Mr. Abhinav from Incessant Nature Science Publishers has worked tirelessly to ensure the successful publication of this inaugural edition



Prof. Suvarna Khadilkar

Editor-in-chief, MOGS chronicles, 2024-7

President MOGS, 2024-5





**Dear Readers,**

It is with great excitement that I present to you the inaugural issue of the MOGS Chronicles. This milestone marks the fruition of our constant efforts to bring quality academics through case-based learning and our desire to engage with our MOGS members.

Journals are invaluable resources to update our knowledge and keep abreast of the latest developments in our field. This journal is a compilation of cases contributed by our MOGS members. Each case featured here not only highlights the complexities of our field but also showcases the successful management of the unique challenges we face in our practice. In this volume, you will find a variety of cases that tackle challenging clinical scenarios, innovative surgical techniques, and the diverse aspects of patient care. These stories serve as learning tool, offering insights that can enhance our practice and ultimately improve patient outcomes.



I would like to express my heartfelt gratitude to MOGS President Dr. Suvarna Khadilkar for leading this initiative and for giving me this opportunity. I extend my thanks to all our authors for their valuable contributions. I would also like to appreciate the hard work of our editorial team and our publisher, Mr. Abhinav, along with his team, for their dedication in delivering this issue.

We would highly appreciate your feedback as readers. On behalf of our editorial board, we hope you enjoy these cases as much as we liked compiling them for you.

Happy reading!

*Riddhi Desai*

Dr Riddhi Desai  
Executive Editor  
MOGS Chronicles





## SUCCESSFUL MANAGEMENT OF OVARIAN ADENOCARCINOMA IN AN IVF PREGNANCY — A RARE CASE REPORT

*Dr. Viveka Jadkar\* Senior resident in OBGYN department, Bombay Hospital Institute of Medical Sciences, Mumbai.*

*\*Corresponding Author — Dr. Shivani Agrawal MS OBGYN (Alumni, BHIMS)*

*Dr. Nitin Pai Dhungat Consultant, Bombay Hospital*

**ABSTRACT:** The occurrence of gynecologic cancer during pregnancy is extremely rare, affecting approximately 4 to 8 pregnancies per 100,000. The frequency of concomitant adnexal tumours in pregnancy is reported to be 0.150- 5.7 %, while ovarian cancer complicates 1 in 15000 - 32000 pregnancies, being the second most common gynaecological cancer during pregnancy following cervical cancer. However, there is increasing incidence of ovarian cancer compared to cervical due to factors such as cervical cancer vaccination and increasing use of ART and increasing maternal age. The diagnosis and management of ovarian cancer during pregnancy remain challenging due to its rarity and the limited data available. Here, we report a case involving a 34-year-old woman diagnosed with a large ovarian adenocarcinoma in the third trimester of pregnancy during routine antenatal scans. The patient was treated with neoadjuvant chemotherapy, followed by an elective cesarean section, cytoreductive surgery, and hyperthermic intraperitoneal chemotherapy (HIPEC).

### Dear readers

This case report (pg. no-3) will make an interesting read. We recommend further reading of few facts about monitoring and safety of chemotherapy during pregnancy CA-125 (58.2 U/mL ) could be used as tumor markers in pregnant patients for epithelial ovarian cancer.<sup>[1]</sup> We are always concerned about safety of chemotherapy during pregnancy. Safety of Mother is most important but literature reports state that it is relatively safer in second and third trimesters, with least risk for fetal complications.

A review of 376 fetuses exposed to chemotherapy in utero states only 2.9% malformations.<sup>[2]</sup> There was 1% neonatal mortality after in utero chemotherapy, which was lower than 17% among the general population globally<sup>[3]</sup>

### References

1. Xing, N.; Wang, L.; Sui, X.; Zhao, C.; Huang, Y.; Peng, J. The Safety of Chemotherapy for Ovarian Malignancy during Pregnancy. *J. Clin. Med.* 2022, 11, 7520. <https://doi.org/10.3390/jcm11247520>
2. Cardonick, E.; Iacobucci, A. Use of chemotherapy during human pregnancy. *Lancet Oncol.* 2004, 5, 283–291.]
3. World Health Statistics. Monitoring Health for the SDGs, Sustainable Development Goals; World Health Organization: Geneva, Switzerland, 2020.



# MOGS Chronicles

Volume 1 | Issue 1 | September 2024

## CONTENTS

### CASE REPORTS

- ❑ **Peripartum Cardiomyopathy – A Conundrum** ..... 1  
*Gandhali Deorukhkar, Nikita Agrawal*
- ❑ **Successful Management of Ovarian Adenocarcinoma in an IVF Pregnancy - A Rare Case Report** ..... 3  
*Viveka Jadkar, Shivani Agrawal, Nitin Pai Dhungat*
- ❑ **A Rare Case of Pregnancy with Gaucher’s Disease**..... 7  
*Priti Vyas, Sharayu Mirji*
- ❑ **Bleeding Trinity: Spontaneous Pelvic and Sigmoid Bowel Hematoma with Cerebral Venous Sinus Thrombosis in a Case of Atraumatic Vaginal Delivery – A Rare Case Report**..... 10  
*Preeti F. Lewis, Kumari Ankita*
- ❑ **A Rare Case of Spontaneous Ovarian Hyperstimulation Syndrome in a Spontaneous Conception with Conservative Management** ..... 13  
*Aishwarya Agrawal, Prerna Gupta, Madhuri Mehendale, Meenal Sarmalkar*
- ❑ **Caesarean Myomectomy in a Patient with Multiple Maternal and Fetal Comorbidities: A Rare Interesting Case Report**..... 15  
*Zeba H. Pathan, Niranjan N. Chavan, Deepali S. Kapote, Shreya Kampoowale, Ashwini S. Sakhalkar, Rutuja A. Mohite*
- ❑ **Genitourinary Endometriosis - A Case Report**..... 18  
*Jil Kadakia, Shivani Agrawal, Sadhana Desai, Prashant Bhamare*
- ❑ **Carcinosarcoma in OHVIRA syndrome: an Enigma**..... 21  
*Rahat Sayyad, Nozer Sheriar, Nikhil Dharmadhikari, Zubin Sheriar*
- ❑ **Hemoperitoneum in a Known Case of Combined Factor V and Factor VIII Deficiency: A Case Report**..... 24  
*K. K. Manasa, Himangi S. Warke, Durga D. Valvi, Priyanka B. Rane, Chandrakala Shanmukhaiah*
- ❑ **Genital Herpes by Herpes Simplex Virus 1 in a Postmenopausal Woman: A Case Report**..... 26  
*Neena Patwardhan*
- ❑ **Save the Uterus! A Case of Large Fibroid with Infertility**..... 28  
*Krutika Ramdin, Reena Wani*



# Peripartum Cardiomyopathy – A Conundrum

Gandhali Deorukhkar, Nikita Agrawal

Department of Maternity and Child Care, Wockhardt Hospital, Mumbai, Maharashtra, India

## Abstract

Peripartum cardiomyopathy is a rare condition that manifests as heart failure during the last month of pregnancy or within 5 months after delivery. This case report describes a 32-year-old woman who presented with symptoms of severe fatigue, dyspnea, and edema 2 months postpartum. Initial evaluations suggested a common postpartum recovery; however, further diagnostic work revealed significantly reduced left ventricular ejection fraction (LVEF) and cardiomegaly. A multidisciplinary approach was employed, including cardiology and obstetrics, leading to the initiation of appropriate heart failure management, including diuretics and beta-blockers. The patient showed improvement in symptoms and LVEF over 6 months and achieved a full recovery ultimately.

**Keywords:** Peripartum cardiomyopathy, Dilated cardiomyopathy, Systolic heart failure

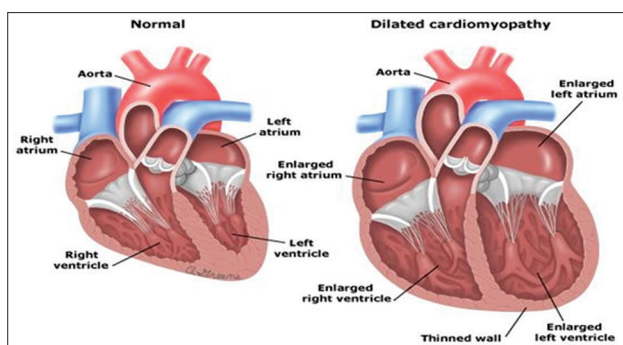
**Address for correspondence:** Nikita Agarwal, Wockhardt Hospital, Mumbai, Maharashtra, India.  
Phone: 9403636366. E-mail: nikitaagrwal2703@gmail.com

## Introduction

Peripartum cardiomyopathy (PPCM) is a rare but severe form of dilated cardiomyopathy occurring towards the end of pregnancy or in early postpartum period characterized by systolic heart failure and reduced left ventricular ejection fraction (LVEF). Figure 1 shows the pathology in dilated cardiomyopathy. Despite its recognition for over a century, PPCM's etiology remains largely unclear, making timely diagnosis and management challenging.<sup>[1]</sup>

## Case Presentation

26-year primigravida presented to the emergency department on the first postpartum day with complaints of significant breathlessness and bilateral lower limb edema. Pregnancy was uneventful until the 26<sup>th</sup> week, when she was diagnosed with pregnancy-induced hypertension and prescribed labetalol 100 mg twice daily. By 27 weeks, she developed bilateral lower limb edema. At 28 weeks, patient developed antepartum haemorrhage, leading to hospitalization. A preterm vaginal delivery was performed, resulting in the birth of a live male baby weighing 890 g and was transferred to neonatal intensive care unit (ICU).



**Figure 1:** Normal heart and dilated cardiomyopathy

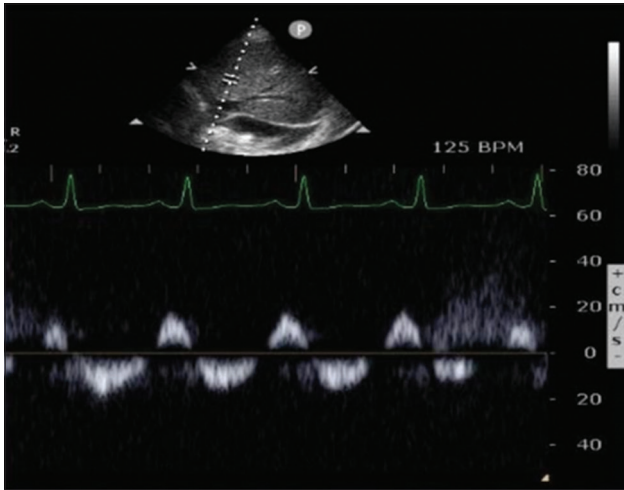
On postpartum day 1, patient presented with severe dyspnea and difficulty in breathing. Examination revealed tachycardia (heart rate 136/min), hypertension (blood pressure 160/110 mmHg), and significant hypoxemia (SpO<sub>2</sub> 80% on room air). Physical examination showed bilateral crackles on respiratory auscultation, a soft abdomen, and a well-contracted uterus.

A 2D echocardiogram [Figure 2] demonstrated global left ventricular hypokinesia with an ejection fraction (LVEF) of 15–20%, moderate mitral regurgitation, inferior vena cava was 14 mm non-collapsing. Arterial blood gases indicated respiratory and metabolic acidosis.

Given the severity of the presentation and the echocardiographic findings, a provisional diagnosis of PPCM with antepartum hemorrhage was made. To assess organ congestion, a venous excess ultrasound score was used, highlighting significant congestion.

Patient was admitted to ICU. A multidisciplinary approach was employed, involving intensivists, cardiologists, and obstetricians. Management plan included mechanical ventilation initiated due to persistent tachypnea and increased work of breathing. Nitroglycerin support started for vasodilation. Renal support with Lasix infusion for diuresis, patient required two sessions of sustained low-efficiency dialysis due to acute kidney injury and for decongestion. Inotropic support with Noradrenaline and dobutamine infusions to support cardiac function was given.<sup>[2]</sup> Invasive monitoring with central venous catheter and arterial line insertion was done.

By the end of day 2, the patient showed improvement, she remained on ventilator support but was hemodynamically stable. Sedation was reduced, inotropic support was tapered, and arterial blood gases improved with no obvious acidosis. On day 3, the patient was extubated, maintained saturation



**Figure 2:** 2D echo

with 2 liters of oxygen, and showed good urine output. By day 4, her condition had stabilized, allowing her transfer from the ICU to the ward. She was discharged on day 7.

## Discussion

This case highlights the critical challenges associated with diagnosing and managing PPCM. Symptoms such as edema and dyspnea in the peripartum period can easily be mistaken for normal pregnancy-related changes or other common conditions like pulmonary embolism and eclampsia.<sup>[3]</sup> As a result, PPCM can often go unrecognized until it reaches a severe stage, as was seen in this case.

The diagnosis of PPCM is particularly challenging due to its symptom overlap with other conditions, which can delay intervention and worsen outcomes.<sup>[4]</sup> Early recognition and prompt treatment are essential in mitigating the severe consequences associated with this condition. The patient's severe presentation, characterized by significant left ventricular dysfunction and subsequent renal failure, underscores the importance of a high index of suspicion and the need for a thorough evaluation in any case of unexplained cardiac symptoms during or after pregnancy.<sup>[5]</sup>

## Conclusion

PPCM remains a rare but serious condition with a potentially devastating impact if not identified and managed promptly. The case presented illustrates the importance of distinguishing PPCM from other common peripartum complications and underscores the need for a multidisciplinary approach to manage such complex cases effectively. Early diagnosis and appropriate management are critical to improving outcomes and reducing morbidity associated with this condition.

## Declaration

### Conflict of interest

None.

## Disclosure

None.

## Informed consent

Informed consent Informed consent was taken from the patient.

## References

1. Agarwal R, Baid R, Sinha D. Peripartum cardiomyopathy in Indian population: A pooled analysis. *J Clin Prev Cardiol* 2021;10:54-7.
2. Regitz-Zagrosek V, Roos-Hesselink JW, Bauersachs J, Blomstrom-Lundqvist C, Cifkova R, Bonis MD, *et al.* 2018 ESC guidelines for the management of cardiovascular diseases during pregnancy. *Eur Heart J* 2018;39:3165-241.
3. Mubarik A, Chippa V, Iqbal AM. Postpartum Cardiomyopathy. 2023 Aug 8. In: StatPearls [Internet]. Treasure Island (FL): StatPearls Publishing; 2024 Jan-. PMID: 30521191.
4. Quevedo S, Bekele C, Thompson PD, Philkhana M, Virani S, Consuegra A, Douglass P, Gertz AM. Peripartum cardiomyopathy and HELLP syndrome in a previously healthy multiparous woman: A case report. *SAGE Open Med Case Rep.* 2020 Dec 21;8:2050313X20979288. doi: 10.1177/2050313X20979288. PMID: 33425357; PMCID: PMC7758651.
5. Wong A, Olusanya O, Watchorn J, Bramham K, Hutchings S. Utility of the venous excess ultrasound (VEXUS) score to track dynamic change in volume status in patients undergoing fluid removal during haemodialysis - the ACUVEX study. *Ultrasound J* 2024;16:23.

## Editor's Note

Peripartum cardiomyopathy (PPCM) is a rare and often overlooked condition affecting postpartum women, characterized by heart failure symptoms occurring toward the end of pregnancy or within the months following delivery. It can be misdiagnosed to be normal pregnancy changes or other common conditions like pulmonary embolism and eclampsia. Recognizing the signs and keeping a high index of suspicion regarding this condition is important. This case report of a 26-year primigravida with APH and preterm delivery at 27 weeks, presented with severe dyspnea on day 1 postpartum. This case sheds light on the challenges of early diagnosis and management of PPCM. Prompt intervention with intensive care unit admission and close collaboration between obstetricians, cardiologists, and intensive care specialist remains the mainstay of management. PPCM is usually diagnosed with an echocardiogram. Treatment for PPCM focuses on improving heart failure symptoms. Women with history of PPCM should be closely monitored during subsequent pregnancies, with serial clinical assessments, echocardiograms, and B-type natriuretic peptide levels. They should also be offered contraception as soon as possible. Long-acting reversible contraception would be the contraceptive of choice in such cases.

**How to cite this article:** Deorukhkar G, Agrawal N. Peripartum Cardiomyopathy – A Conundrum. *MOGS Chronicles* 2024;1(1):1-2.

# Successful Management of Ovarian Adenocarcinoma in an IVF Pregnancy - A Rare Case Report

Viveka Jadkar, Shivani Agrawal, Nitin Pai Dhungat

Department of Obstetrics and Gynecology, Bombay Hospital Institute of Medical Sciences, Mumbai, Maharashtra, India

## Abstract

The occurrence of gynecologic cancer during pregnancy is extremely rare, affecting approximately 4–8 pregnancies per 100,000. The frequency of concomitant adnexal tumours in pregnancy is reported to be 0.150–5.7%, while ovarian cancer complicates 1 in 15000–32,000 pregnancies, being the second most common gynaecological cancer during pregnancy following cervical cancer. However, there is increasing incidence of ovarian cancer compared to cervical due to factors such as cervical cancer vaccination and increasing use of antiretroviral therapy and increasing maternal age. The diagnosis and management of ovarian cancer during pregnancy remain challenging due to its rarity and the limited data available. Here, we report a case involving a 34-year-old woman diagnosed with a large ovarian adenocarcinoma in the third trimester of pregnancy during routine antenatal scans. The patient was treated with neoadjuvant chemotherapy, followed by an elective cesarean section, cytoreductive surgery, and hyperthermic intraperitoneal chemotherapy.

**Keywords:** Ovarian cancer, Adenocarcinoma, CA 125, Neoadjuvant chemotherapy, Cytoreductive surgery, HIPEC

**Address for correspondence:** Viveka Jadkar, Department of Obstetrics and Gynecology, Bombay Hospital Institute of Medical Sciences, Mumbai, Maharashtra, India. E-mail: dr.vivekajadkar@gmail.com

## Introduction

Ovarian cancer is the second most frequent gynaecological cancer complicating pregnancy.<sup>[1]</sup> With the use of routine ultrasound examination in every patient, the incidence of abdominal masses diagnosed during pregnancy has increased and is estimated to be 2–10% of all pregnancies.<sup>[2]</sup> Most common adnexal mass associated during pregnancy is a functional cyst. Majority of the benign masses are dermoid cyst, serous cystadenomas, rarely endometriomas, hydrosalpinx and leiomyomas.<sup>[3]</sup> Only 3–6% of all ovarian cysts associated with pregnancy are malignant.<sup>[4]</sup> Malignant germ cell tumours are the most common ovarian malignancies during pregnancy, while epithelial cancers are reported less frequently and are of low malignant potential.<sup>[5]</sup> Incidence of epithelial ovarian cancer (EOC) is 1:12,000 to 1:50,000 of all pregnancies. The rare occurrence and scant data prompted the reporting of the present case.

## Case Report

A 34-year-old primigravida with *in vitro* fertilization conception was referred to the Department of Obstetrics and Gynaecology of Bombay Hospital at 30 weeks of gestation with dull aching abdominal pain and inability to perceive foetal movements since few weeks. She also had loss of appetite and loss of weight during this pregnancy. On abdominal examination, there was an exaggerated fundal height and a huge abdominopelvic mass, round,

non-ballotable, with ill-defined edges. Foetal poles were not felt separately. On pelvic ultrasound examination a large complex heterogenous mass of 20×11×11 cm with cystic component in the right pelvis with a single live intrauterine gestation ~26 weeks with AFI of 8 cm (mild oligohydramnios) with foetal growth restriction [Figure 1] was seen. Pelvic magnetic resonance imaging (MRI) showed a gravid uterus of 7 months with a large complex multiloculated cyst in right pelvis region 22×11×12 cm, mild to moderate ascites and few enlarged retroperitoneal lymph nodes, morphologically and structurally suspicious of malignancy [Figure 2]. Lab investigations showed CA125–5375 U/ML. LDH- 497 MU/ML.

An ultrasound guided right ovarian mass biopsy was done which confirmed the diagnosis of adenocarcinoma of ovary [Figure 3]. A multidisciplinary team of oncologist and neonatologist were involved. 6 cycles of neoadjuvant chemotherapy were given to the mother with Carboplatin and Paclitaxel. Patient was weekly monitored for foetal well-being, which showed significant improvement in AFI and estimated foetal weight. A weekly blood test which included complete hemogram, liver function test and renal function test were also being done. Prophylactic antenatal corticosteroids cover was given to the mother at 30 weeks.

An elective caesarean section with a Pfannenstiel incision was done at 36 weeks and a healthy female baby of 2.3 kg was delivered. Evidence of right ovarian fluid filled cyst of ~10×8×11 cm removed in toto [Figure 4]. Evidence of

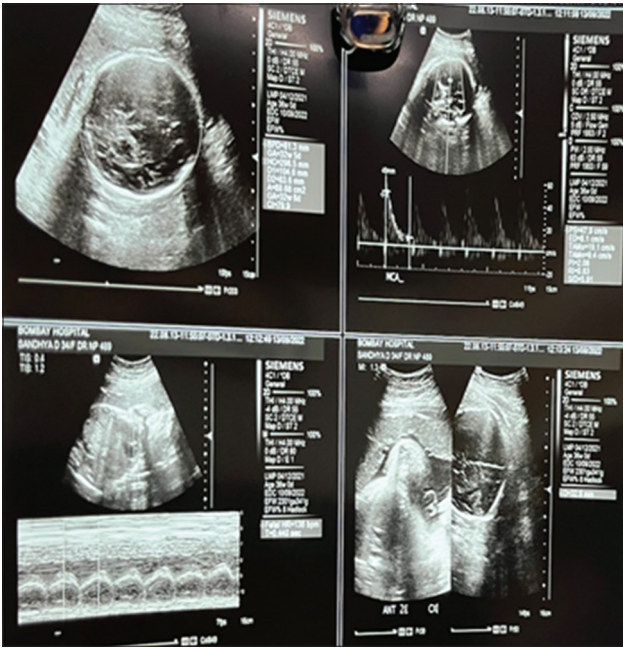


Figure 1: Ultrasound findings

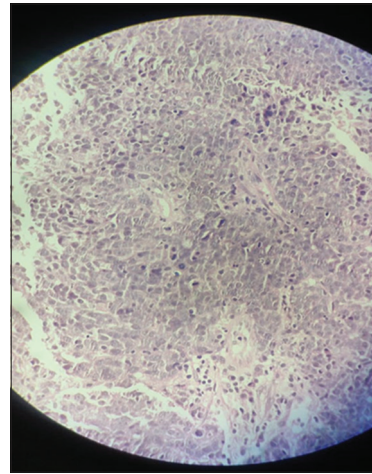


Figure 3: Adenocarcinoma of ovary

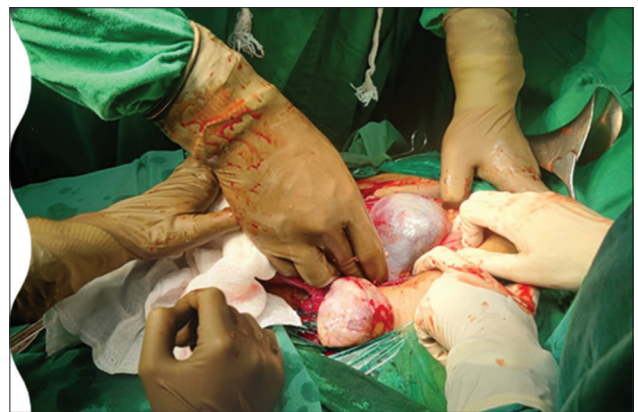

Figure 4: Intra operative finding of right ovarian cyst

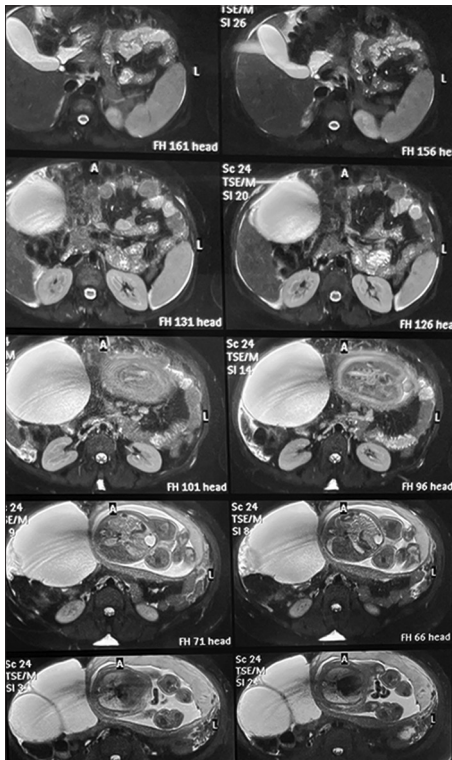


Figure 2: Pelvic MRI

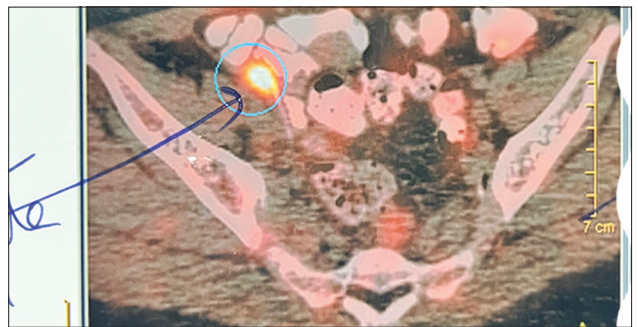


Figure 5: PET scan showing small soft tissue FDG uptake

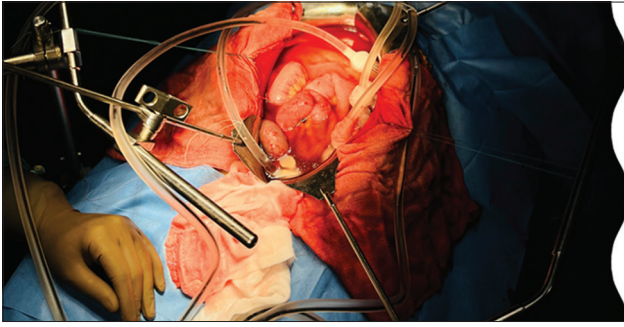
enlarged left ovary which was also removed in toto and sent for histopathological examination. Patient was stable post op and allowed to breastfeed for a month. The histopathological findings confirmed bilateral ovarian adenocarcinoma. Adjuvant chemotherapy with Carboplatin and Paclitaxel was restarted one month post-surgery for 3 cycles. A positron emission tomography computed tomography (CT) scan showed small soft tissue FDG uptake ~2 cm with no obvious omental thickening [Figure 5]. CA125 was 8 U/mL. Cytoreductive surgery (hysterectomy with omentectomy) with hyperthermic intraperitoneal chemotherapy with

Cisplatin 64 mg was done 3 months post Caesarean section [Figures 6 and 7]. She has undergone 9 cycles of adjuvant chemotherapy post-surgery. CT scan shows no recurrence or identifiable lesion at one yearly follow-up.

## Discussion

The incidence of adnexal masses diagnosed during early pregnancy is 1–4%, and majority are of ovarian origin.<sup>[6]</sup> Around 2–6% of ovarian tumors associated with pregnancy are malignant.<sup>[7]</sup> These tumors are more commonly found in primigravidas and are typically diagnosed at an early stage (below stage 1c per FIGO staging) through ultrasound.<sup>[8]</sup> Ultrasound is the preferred diagnostic tool due to its high sensitivity and specificity in characterizing the morphology of abdominal





**Figure 6:** Cytoreductive surgery, hysterectomy with omentectomy was done



**Figure 7:** HIPEC with Cisplatin 64mg

masses. Features indicating malignancy include large size, solid or complex appearance, internal septations, irregular borders, increased vascularity, and low blood flow resistance. However, ultrasound cannot reliably differentiate between benign and low malignant potential tumors, necessitating further imaging, such as MRI, which is safe in the second and third trimesters and may reveal extraovarian spread.<sup>[9]</sup>

CA125 is produced by 80–90% of EOCs, but its levels may be elevated during pregnancy or due to complications such as HELLP syndrome, preeclampsia, or miscarriage. Elevated inhibin, human chorionic gonadotropin, and alpha-fetoprotein may suggest germ cell or sex cord-stromal ovarian tumors. Managing malignant tumors during pregnancy is challenging, as both maternal and fetal health must be carefully considered.<sup>[10]</sup>

Surgical resection is indicated in case of ovarian tumours during pregnancy that are sized >7 cm, suggestive of malignancy and are associated with clinical symptoms. Patients with advanced stage disease require chemotherapy, which should be avoided in the first trimester.<sup>[11]</sup> It is possible to administer chemotherapy from 14 weeks gestational age onwards with specific attention to prenatal care. The European Society of Medical Oncology guidelines suggest that the decision to administer chemotherapy during pregnancy should align with the same protocols used for non-pregnant patients. The current standard adjuvant chemotherapy regimen for treating epithelial ovarian carcinoma is a combination of Carboplatin and Paclitaxel.<sup>[12]</sup> Reports indicate that administering carboplatin during the second trimester has no significant adverse effects on the foetus.<sup>[13]</sup>

This case of EOC during pregnancy emphasizes the impact of chemotherapy on pregnancy outcomes. The use of multi-agent chemotherapy during pregnancy is becoming increasingly common. Early-stage ovarian carcinoma

diagnosed during pregnancy should be treated promptly without unnecessary delays.

## Conclusion

The association of ovarian malignancy with pregnancy is rare. The timing of delivery in patients with ovarian cancer depends on both the cancer stage and gestational age. Treatment decisions should involve a multidisciplinary team, including gynecologists, oncologists, and neonatologists. This case highlights that the primary focus should be on ensuring the patient's prognosis and quality of life. While chemotherapy during the second trimester appears to be relatively safe, the potential risks of this treatment approach must still be carefully considered.

## Declaration

### Conflict of interest

None.

### Disclosure

None.

### Informed consent

Informed consent was taken from the patient

## References

- Palmer J, Vatish M, Tidy J. Epithelial ovarian cancer in pregnancy: A review of the literature. *BJOG* 2009;116:480-91.
- Behtash N, Karimi Zarchi M, Modares Gilani M, Ghaemmaghami F, Mousavi A, Ghotbizadeh F. Ovarian carcinoma associated with pregnancy: A clinicopathologic analysis of 23 cases and review of the literature. *BMC Pregnancy Childbirth* 2008;8:3.
- Nick AM, Schmeler K. Adnexal masses in pregnancy. *Perinatology* 2010;1:13-9.
- Zhao XY, Huang HF, Lian LJ, Lang JH. Ovarian cancer in pregnancy: A clinicopathologic analysis of 22 cases and review of the literature. *Int J Gynecol Cancer* 2006;16:8-15.
- Yakasai IA, Bappa LA. Diagnosis and management of adnexal masses in pregnancy. *J Surg Tech Case Rep* 2012;4:79-85.
- Elhalwagy H. Management of ovarian masses in pregnancy. *Trends in Urology Gynaecology and Sexual Health* 2009;14:14-8.
- Huang HP, Fang CN, Kan YY. Chemotherapy for ovarian mucinous cystadenocarcinoma during pregnancy: A case report. *Eur J Gynaecol Oncol* 2004;25:635-6.
- Takeuchi T, Suzuki S, Hayashi Z, Shinagawa T, Araki T. Primary ovarian tumor undergoing surgical management during pregnancy. *J Nippon Med Sch* 2002;69:39-42.
- de Haan J, Verheecke M, Amant F. Management of ovarian cysts and cancer in pregnancy. *Facts Views Vis Obgyn* 2015;7:25-31.
- Han SN, Verheecke M, Vandenbroucke T, Gziri MM, Van Calsteren K, Amant F. Management of gynecological cancers during pregnancy. *Curr Oncol Rep* 2014;16:415.
- Skrzypczyk-Ostaszewicz A, Rubach M. Gynaecological cancers coexisting with pregnancy - a literature review. *Contemp Oncol (Pozn)* 2016;20:193-8.
- Amant F, Calsteren KV, Halaska MJ, Gziri MM, Hui W, Lagae L, *et al.* Long-term cognitive and cardiac outcomes after prenatal exposure to chemotherapy in children aged 18 months or older: An observational study. *Lancet Oncol* 2012;379:558, 570, 580.
- Mendez LE, Mueller A, Salom E, Gonzales-Quintero VH. Paclitaxel and carboplatin chemotherapy administered during pregnancy for advanced epithelial ovarian cancer. *Obstet Gynecol* 2003;5:1200-2.

**How to cite this article:** Jadkar V, Agrawal S, Dhungat NP. Successful Management of Ovarian Adenocarcinoma in an IVF Pregnancy - A Rare Case Report. *MOGS Chronicles* 2024;1(1):3-6.

## Editor's Note

This case report presents a rare instance of EOC diagnosed during pregnancy, highlighting the complexities of management for a good maternal and fetal outcome. It also necessitates the need for awareness of this condition. Ultrasound is an optimum diagnostic tool, but it cannot differentiate between benign and low malignant potential tumours, therefore, MRI is required for further evaluation. It is safe to perform in 2<sup>nd</sup> trimester. Chemotherapy is safe in 2<sup>nd</sup> trimester and should be started as it would be in a non-pregnant patient. Prompt diagnosis, timely intervention, multidisciplinary approach and successful integration of neoadjuvant chemotherapy are essential for a better outcome in these cases.

# A Rare Case of Pregnancy with Gaucher's Disease

Priti Vyas, Sharayu Mirji

Department of Obstetrics and Gynecology, Surya Hospital, Santacruz West, Mumbai, Maharashtra, India

## Abstract

Medical disorders in pregnancy present with challenges for the obstetrician often requiring a multidisciplinary support. We report a rare case of pregnancy with Gaucher's disease (GD), a lysosomal storage disorder. A 30-year-old primigravida incidentally found massive splenomegaly at her first antenatal visit. Further investigations confirmed diagnosis of Type I GD. Complications included persistent anemia, thrombocytopenia which were but managed conservatively, pregnancy carried till term and delivered by caesarean section. This case report highlights the successful management of GD in pregnancy with a healthy outcome for both mother and baby.

**Keywords:** Gaucher disease, Gaucher cells, Lysosomal storage disorder, splenomegaly

**Address for correspondence:** Priti Vyas, Consultant Obstetrician and Gynecologist, Surya Hospital, Santacruz West, Mumbai, Maharashtra, India. Mobile: 9869428728. E-mail: drprityas@gmail.com

## Introduction

Gaucher disease (GD) is lysosomal storage disorder- autosomal recessive, caused by inherited deficiency of enzyme  $\beta$ -glucocerebrosidase leading to accumulation of glucocerebroside (glucosylceramide) and several related compounds that are ordinarily degraded to glucose and lipid, to accumulate within lysosomal cells of reticulo-endothelial system resulting in spectrum of visceral, haematologic and skeletal symptoms.

There are five subtypes, non-neuropathic/adult (Type 1) which is most common,

Acute neuropathic/infantile (Type 2), Chronic/subacute neuropathic/juvenile (Type 3) which occurs in first decade of life, Perinatal lethal form (Type 4) and Cardiovascular form.<sup>[1]</sup>

The standardized birth incidence in general population is 0.4–5.8/100,000, with prevalence of 0.7–1.8/100,000. Type 1 GD (GD1) is most prevalent (90% of times). Especially prevalent in Ashkenazi Jewish population 1:850, and lower in non-Jewish populations, 1:40,000 to 1:86,000 live births.

Women in reproductive age group form a large proportion of GD1 population. Pregnancy with GD poses unique challenges with increased risk of anemia, thrombocytopenia and osteonecrosis. The challenges are at all stages of pregnancy and at time of delivery for both the obstetrician and anaesthetist. Here, we report a rare case of pregnancy with type 1 GD, managed with multidisciplinary support with a successful outcome.

## Case Report

A primigravida 30 years old, in a non-consanguineous marriage, presented at 6.2 weeks of gestation with an

enlarged spleen reaching upto umbilicus and a palpable liver [Figure 1]. With no previous significant history. Rest of the examination was normal except thin built and pallor.

On ultrasound, massive splenomegaly 25 cms seen and moderate hepatomegaly with Intrauterine live gestation of 6.2 weeks. Hematological investigations revealed pancytopenia. (hemoglobin [Hb] - 9.4 g/dL, white blood cell - 4100 cells/cmm, platelet - 62,000/cmm).

A hematologist was consulted followed by bone marrow biopsy showed numerous large histiocytes with finely fibrillar cytoplasm-crinkled or wrinkled-paper like, expressing CD-68 and TRAP, consistent with diagnosis of GD. Enzyme analysis showed reduced activity of b-glucosidase in leucocytes (16.1% of normal) and elevated levels of chitotriosidase in plasma (72 folds high). Whole genome sequencing of couple revealed a compound heterozygous variant in the GBA gene of patient and normal variant in husband.

Patient being asymptomatic, a conservative line of management was followed with regular monitoring of blood counts. Anemia was corrected [Table 1] with parenteral iron - 3 doses.

Fetal growth monitoring revealed mild fetal growth restriction but normal doppler flows. She went in spontaneous labor at 36.4 weeks with Hb = 10.8 g/dL and platelet = 1.03 lac/cmm. With normal coagulation profile. There was a massive spleen and liver with risk of splenic rupture and high floating head; normal delivery was not advisable and emergency LSCS under spinal anaesthesia was done. She delivered 2.4 kg healthy male.

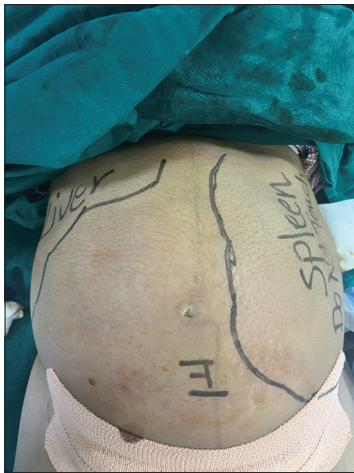Blood and platelets were kept reserved and active management of third stage was done with uterotonics. No transfusion was needed and post-partum period was

uneventful. Baby was evaluated by the neonatologist and storage disorder was ruled out. Patient is now following up with the haematologist. She has not required any intervention till date.

## Discussion

Patients with type 1 GD, which is the non-neuronopathic and most common form of the disease, can remain undiagnosed till later in life or may be diagnosed incidentally with painless splenomegaly, anemia or thrombocytopenia or present with abdominal pain, chronic fatigue, bleeding tendencies.

In GD hepatomegaly with raised liver enzymes can lead to portal hypertension and cirrhosis. Skeletal involvement with bone pain, acute bone crisis, pathologic fractures, vertebral collapse is due to decreased mineral density, marrow infiltration, and infarction of bone. Marrow fibrosis and osteosclerosis result in localized loss of hematopoiesis. Cytopenias are due an intrinsic defect in addition to hypersplenism and bone marrow infiltration with Gaucher cells. Thrombocytopenia results from splenic sequestration and occasionally marrow failure. The increased bleeding tendency in patients with GD1 is related to thrombocytopenia, coagulation abnormalities, and defective platelet function. A radiologic feature seen is an Erlenmeyer flask deformity of the distal femur. Rarely, patients may present with portal hypertension, parkinsonism, pulmonary hypertension or multiple myeloma.<sup>[2]</sup> Pregnancy is known to exacerbate disease manifestations with increased risk of spontaneous miscarriage, antepartum and postpartum haemorrhage.<sup>[3]</sup>



**Figure 1:** Demarcating splenomegaly and hepatomegaly

Diagnosis can be done by measurement of glucocerebrosidase activity in peripheral blood leucocytes (<15% of normal). Molecular diagnosis with polymerase chain reaction based tests can identify GBA1 mutations. Monitoring is done by complete blood count (CBC), liver function test (LFT) and coagulation profile. Ultrasonography (USG) abdomen for organomegaly, X-ray or magnetic resonance imaging (MRI) for skeletal deformities, DEXA scans for osteopenia. Bone marrow aspiration in GD shows Gaucher cells, 20–100 mm-wrinkled paper appearance due to intracytoplasmic substrate accumulation and stain strongly positive with Periodic acid Schiff.

Treatment of Type 1 GD comprises of enzyme replacement therapy (ERT), which includes imiglucerase, valaglucerase alfa and taliglucerase alfa; indicated in patients who exhibit sign-symptoms of the disease. It is very effective in reversing the visceral and haematologic manifestations of the disease. The dose is 15–60 U/kg administered every alternate week. An average decrease of 25% in liver-spleen size and increased haemoglobin-platelet count over 6–12 months is noted. Skeletal disease is relatively slow to respond. The use of ERT in symptomatic patients during pregnancy has shown to reduce complications associated with GD, but it is recommended to initiate during pregnancy only if there is a worsening of disease parameters. Those who are already on treatment are advised to continue the same during pregnancy with dose adjustments according to symptoms.

Another line of treatment is with glucosylceramide synthase inhibitors or substrate reduction therapy (SRT) including miglustat and eliglustat. There is limited data on the use of SRT in human pregnancy.

Anaesthesia in patients with GD requires careful consideration and planning.

The anaesthesiologically relevant aspects in GD are related to haematopoietic system with anemia, thrombocytopenia, impaired coagulation capacity and leucopenia with impaired immune competence, impaired lung function, impaired central nervous system function including epilepsy and dysphagia and pulmonary arterial hypertension in adult patients e.g. receiving ERT.

Regional anaesthesia is preferred unless it is precluded by severe thrombocytopenia. Pre anaesthesia workup including a CBC and coagulation profile is a must. Increased intra and post operative bleeding can occur despite normal haematological parameters, so necessary blood products should be kept available. Substrate-reducing therapy may interfere with perioperative drug therapy. Eliglustat is

**Table 1:** Summary of CBC and interventions done.

Time	Hb (g/dL)	WBC count	Platelet count (per cmm)	Intervention
6 weeks	9.4	4100	62,000	Nil
13 weeks	8.4	3410	90,000	IV Iron FCM 1 g
17 weeks	7.2	2690	1.2 lac	IV Iron FCM 1 g
24 weeks	8.6	2800	1.05 lac	IV Iron FCM 1 g
Pre delivery 36 weeks	9.6		1.03 lac	PCV reserved

WBC: White blood cell

metabolized strongly by hepatic CYP2D6 – enzymes and to a lesser extent by CYP3A. Thus, all inhibitors of these pathways may increase toxicity of eligustat and should be avoided. Also special care should be taken in patient positioning and transfer in view of possible osteopenia.

## Conclusion

In conclusion, this case demonstrates the importance of thorough initial assessment and multidisciplinary team approach goes a long way in successful management of pregnancy with Gaucher's disease. It also underscores the need for more research and studies in this area for a better understanding of this condition in pregnancy.

## Declaration

### Conflict of interest

None.

### Disclosure

None.

### Informed consent

Informed consent Informed consent was taken from the patient.

## References

1. Available from: <https://rarediseases.org/rare-diseases/gaucher-disease> [Last accessed on 2024 Sep 09].
2. Sidransky E. Available from: <https://emedicine.medscape.com/>

3. Komninaka V, Flevari P, Marinakis T, Karkaletsis G, Malakou L, Repa K. Outcomes of pregnancies in patients with Gaucher's disease: The experience of a center of excellence on rare metabolic disease- Gaucher Disease in Greece. *Eur J Obstet Gynecol Reprod Biol* 2020;254:181-7. article/944157-print [Last accessed on 2023 Oct ???].

## Editor's Note

GD is a rare genetic disorder that affects the body's ability to metabolize certain substances. It can complicate pregnancy with complications like, bone deformities, anemia, thrombocytopenia, and neurological issues. This case report highlights the challenges of managing pregnancy in a patient with Type 1 GD, emphasizing the need of a multidisciplinary approach. Diagnosis can be done by measurement of glucocerebrosidase activity in peripheral blood leucocytes. Monitoring is done by CBC, LFT and coagulation profile. USG abdomen for organomegaly, X-ray or MRI for skeletal deformities, DEXA scans for osteopenia. Treatment of Type 1 GD comprises of ERT. Regional anaesthesia is preferred unless it is precluded by severe thrombocytopenia. The successful management of anemia and thrombocytopenia, along with careful monitoring and timely interventions are crucial for a good maternal and fetal outcome.

**How to cite this article:** Vyas P, Mirji S. A Rare Case of Pregnancy with Gaucher's Disease. *MOGS Chronicles* 2024;1(1):7-9.

# Bleeding Trinity: Spontaneous Pelvic and Sigmoid Bowel Hematoma with Cerebral Venous Sinus Thrombosis in a Case of Atraumatic Vaginal Delivery – A Rare Case Report

Preeti F. Lewis, Kumari Ankita

Department of Obstetrics and Gynecology, at G.G.M.C and Sir J.J. Group of Hospitals, Mumbai, Maharashtra, India

## Abstract

Pelvic hematoma is a localized collection of blood outside blood vessels following trauma or injuries to blood vessels in pelvic cavity. This is a rare case of pelvic hematoma following atraumatic preterm vaginal delivery developing vulval hematoma on day 2 of delivery with sigmoid bowel hematoma and cerebral venous sinus thrombosis in a case of eclampsia.

**Keywords:** Spontaneous pelvic hematoma, Sigmoid Hematoma, Atraumatic delivery, vulval hematoma

**Address for correspondence:** Dr. Kumari Ankita, Resident, Department of Obstetrics & Gynaecology, G.G.M.C & Sir, J.J. Group of Hospitals, Mumbai, Maharashtra, India. Email: ankitamegha21@gmail.com

## Introduction

Pelvic hematoma is a rare but serious complication that can arise during or after childbirth, often resulting from trauma or vascular injury. Eclampsia itself creates a hypercoagulable state, increasing the risk of thrombotic events, while the physiological changes during pregnancy can exacerbate hemorrhagic conditions. The combination of pelvic and sigmoid hematomas, alongside CVST, is rare and can be life threatening unless prompt diagnosis and appropriate management is done. We present to you this rare case of multiple thrombotic event in a young primigravida with eclampsia with an atraumatic vaginal delivery.

## Case Presentation

A 22-year-old female, primigravida, 32 weeks of gestational age with no history of raised blood pressure (BP) or any coagulopathy, had one episode of convulsion at home following which she visited nearby a maternity home where her BP was found to be raised and within 4 h she delivered a preterm male child of 1.8 kg. Immediate post delivery, the patient had another episode of generalized tonic clonic seizures and was shifted to CCU. Post delivery on day 1, the patient's Hb was 11.2 g%, total counts 12k, platelet 132k with healthy episiotomy on the left side and no active bleeding on local examination. Day 2 post partum, patient started complaining of severe perineal pain. On examination patient was pale and local examination revealed right sided vulval hematoma. Repeat complete blood count was done which showed the Hb had significantly dropped to 5.7 g%, total counts were raised to 20.3 k, platelets were 146 k. Patient was then referred to our hospital for further management. On examination her

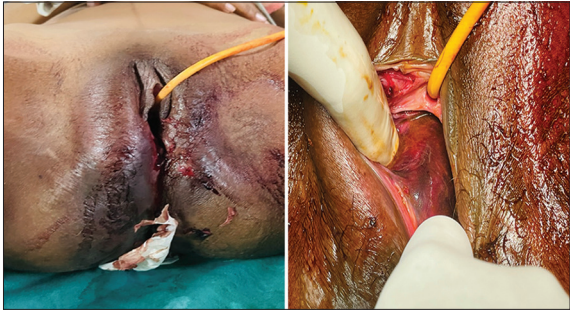
general condition was moderate, Pallor ++ and mild pedal oedema. Pulse was 130 bpm, BP was 100/70 mmHg and SPO<sub>2</sub> 99% on room air with normal systemic examination, deep tendon reflex was found to be brisk, no premonitory signs, Urine Albumin showed +3. Urine output was adequate, clear in colour. On per abdominal examination, it was soft, no guarding/tenderness/rigidity. Uterus was well retracted. Per speculum examination revealed vulval hematoma present on the right side. Episiotomy sutures present on left side. There was no active bleeding. On per vaginal examination there was a right lateral wall hematoma of 5 × 6 cm as shown below [Figure 1].

Investigations revealed, Hb of 5.7 g%, total counts of 20.3 k, platelets were 146 k, lactate dehydrogenase was 941 IU/L, bleeding time was 1 min 45 s and clotting time was 5 min: 15 s, D dimer was 4.72 mg/l. Rest of the parameters were normal.

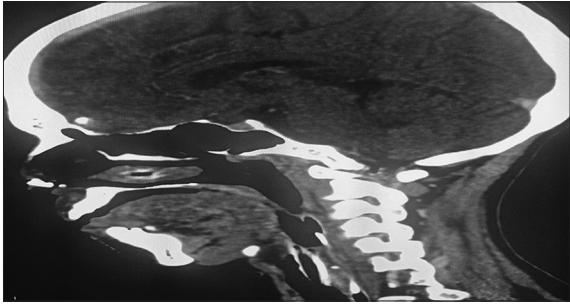
Pelvic ultrasound (USG) showed pelvic hematoma of 7.1 × 5.6 × 7.1 cm adjacent to lower uterine segment and cervix on right. Uterus bulky consistent with post-partum status. USG Vulval region showed ill-defined hypoechoic fluid in superficial plane of bilateral labia. Computed tomography (CT) scan abdomen reported as bilateral vulval and pelvic hematoma of 8.9 × 5 × 9 cm located medially to right pelvic wall and right psoas muscle with oedematous sigmoid colon.

CT scan brain was done which showed partial contrast filling defect noted in frontal portion of superior sagittal sinus s/o cerebral venous sinus thrombosis [Figure 2].

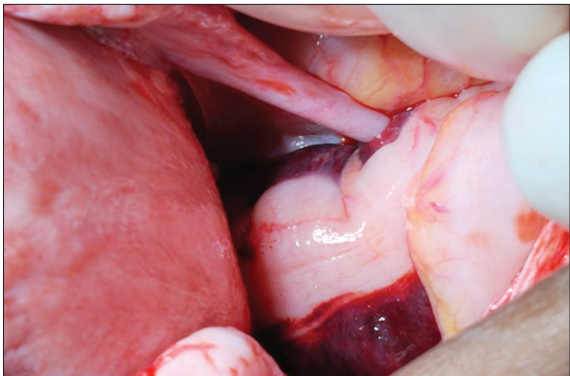
Vaginal exploration was done under GA and 300 g clots removed from vulval hematoma on right side. However,



**Figure 1:** Post partum spontaneous atraumatic vulval hematoma



**Figure 2:** Computed tomography scan imaging of brain showing partial contrast filling defect in frontal Portion of Superior sagittal sinus



**Figure 3:** Intra operative finding of sigmoid bowel hematoma

episiotomy wound present over the left vulva was intact. Based on CT scan findings, the decision of exploratory laparotomy taken. Intraoperatively, a hematoma of  $3 \times 2$  cm had encompassed the lateral and posterior aspects of the sigmoid-rectal junction with no hemoperitoneum [Figure 3]. Bowel tracing revealed no abnormality, hence decision was taken to manage the bowel hematoma conservatively.

Post operatively patient received a blood transfusion and was started on Injection LMWH 0.6 cc subcutaneously twice a day for CVST with INR and activated partial thromboplastin time monitoring. She was discharged after

14 days on Tablet Dabigatran 150 mg twice a day with advise for follow up after 2 weeks.

## Conclusion

Pregnancy itself is a hypercoagulable state which is aggravated by haemoconcentration state seen in eclampsia.<sup>[1]</sup> This leads to multiple critical haemorrhages at various sites including atraumatic pelvic hematoma, sigmoid hematoma as well as cerebral venous sinus thrombosis.<sup>[2,3]</sup>

Pelvic hematoma when coupled with sigmoid bowel hematoma as well as cerebral venous sinus thrombosis can become life threatening unless prompt diagnosis and appropriate management is done.<sup>[4,5]</sup> A combination of physical examination, imaging tests and tailored treatment can prevent significant morbidity as well as mortality associated with such hematomas.

## Declaration

### Conflict of interest

None.

### Disclosure

None.

### Informed consent

Informed consent Informed consent was taken from the patient.

## References

1. Zeeman GG, Cipolla MJ, Cunningham GF. Cerebrovascular (patho) physiology in preeclampsia/eclampsia. In: Lindheimer M, Roberts J, Cunningham G, editors. Chesley's Hypertensive Disorders in Pregnancy. San Diego, CA: Elsevier; 2009. p. 227-48.
2. Dag ZO, Işık Y, Simsek Y, Tulmac OB, Demiray D. HELLP syndrome and cerebral venous sinus thrombosis associated with factor V Leiden mutation during pregnancy. Case Rep Obstet Gynecol 2014;2014:582890.
3. Singh A, Singh S, Vardhan S. A rare case of post-partum cerebral venous sinus thrombosis. Int J Reprod Contracept Obstet Gynecol 2018;7:762-5.
4. Bacalbaşa N, Bohilţea RE, Dumitru M, Turcan N, Cîrstoiu MM. Subserosal hematoma of the sigmoid colon after vaginal delivery. J Med Life 2017;10:76-9.
5. Tseng JY, Lin IC, Lin JH, Chang CM, Chao WT, Wang PH. The optimal approach for management of postpartum vulva hematoma: Report of three cases. Taiwan J Obstet Gynecol 2020;59:780-3.

**How to cite this article:** Lewis PF, Ankita K. Bleeding Trinity: Spontaneous Pelvic and Sigmoid Bowel Hematoma with Cerebral Venous Sinus Thrombosis in a Case of Atraumatic Vaginal Delivery – A Rare Case Report. MOGS Chronicles 2024;1(1):10-12.

## Editor's Note

This rare case report, serves as a valuable reminder of the challenges we face in obstetric care. What makes this case significant is the combination of pelvic and sigmoid hematomas, alongside cerebral venous sinus thrombosis, all of which are critical conditions that are related to significant morbidity and mortality and pose significant challenges in management. Pelvic atraumatic hematomas can arise due to the hypercoagulable state of pregnancy, particularly in cases of eclampsia that exacerbate this, leading to severe complications such as blood loss and associated morbidity. Similarly, sigmoid hematomas can result from pressure during labour or delivery, necessitating prompt diagnosis and intervention to prevent further complications. The occurrence of cerebral venous sinus thrombosis, which may present with neurological symptoms and requires immediate attention. The report illustrates the importance of timely diagnosis and intervention to improve patient outcomes. A multidisciplinary collaboration helps to manage complex obstetric emergencies effectively.



# A Rare Case of Spontaneous Ovarian Hyperstimulation Syndrome in a Spontaneous Conception with Conservative Management

Aishwarya Agrawal, Prerna Gupta, Madhuri Mehendale, Meenal Sarmalkar  
Department of Obstetrician and Gynecologist, LTMMC, Mumbai, Maharashtra, India

## Abstract

Ovarian hyperstimulation syndrome is a rare, yet fatal complication seen in *in vitro* fertilization characterized by cystic enlargement of ovaries with a third space fluid loss. We report a case of spontaneous ovarian hyperstimulation syndrome (OHSS) in a 22 year old, third gravida, with previous two full term vaginal deliveries, presenting to us at 8 weeks of amenorrhea with complaints of pain in abdomen, abdominal distention and breathlessness since 3 days. There was no history of any hormone use prior to or during this pregnancy. Ultrasound was suggestive of a gestational sac corresponding to 5 weeks pregnancy with absence of fetal pole with bilateral bulky ovaries showing fishnet appearance with moderate ascites and bilateral pleural effusion. Hence, a diagnosis of spontaneous OHSS was made. Patient was admitted for conservative management using intravenous fluids and thromboprophylaxis along with regular monitoring. Therapeutic paracentesis and thoracocentesis were done twice to provide symptomatic relief. Since patient was not desirous of this pregnancy, she was undertaken for first trimester medical termination of pregnancy by dilatation and evacuation in view of severe OHSS on day 3 after admission. Post procedure, she was started on cabergoline (0.5 mg) and was discharged on attaining symptomatic relief. Management of OHSS is dependent on the stage at which it is diagnosed. Early recognition and timely management of such cases ensures prevention of fatal complications yielding good outcome.

**Keywords:** OHSS, Spontaneous Hyperstimulation, Hyperstimulation syndrome

**Address for correspondence:** Aishwarya Agrawal, Department of Obstetrician and Gynecologist, LTMMC, Mumbai, Maharashtra, India. Mobile: +91-7666517587. E-mail: draishwarya96@gmail.com

## Introduction

Ovarian hyperstimulation syndrome is a rare, yet fatal complication seen in *in vitro* fertilization characterized by cystic enlargement of ovaries with a third space fluid loss due to ovarian neoangiogenesis and increased vascular permeability.<sup>[1]</sup> This leads to a plethora of symptoms with varying severity. Spontaneous ovarian hyperstimulation syndrome (OHSS) is a rare event reported in 0.2–1.2% cases occurring spontaneously in pregnancy without exogenous human chorionic gonadotropin (hCG) use.<sup>[2]</sup>

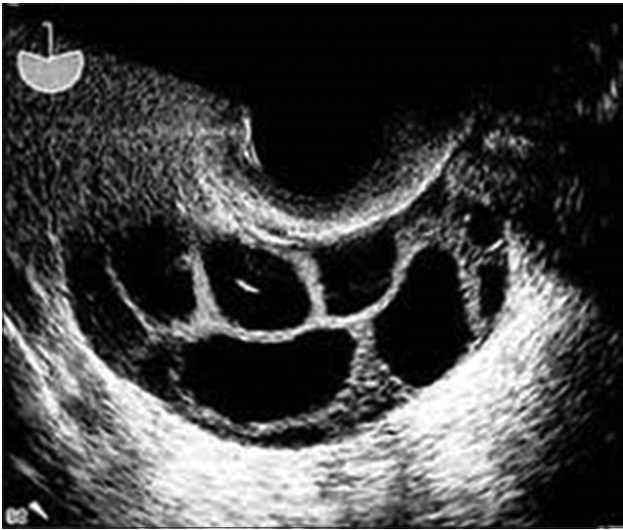## Case Report

We report a case of spontaneous OHSS in a 22 year old, third gravida, with previous two full term vaginal deliveries, presenting to us at 8 weeks of amenorrhea with complaints of pain in abdomen, abdominal distention and breathlessness since 3 days. There was no history of any hormone use prior to or during this pregnancy. A battery of investigations were done along with ultrasound was done which was suggestive of a gestational sac corresponding to 5 weeks pregnancy with absence of fetal pole with bilateral bulky ovaries showing fishnet appearance with increased bilateral adnexal vascularity [Figures 1 and 2]. Right ovary measured 8.4 × 4.8 × 6.4 cm (80 cc) and left ovary

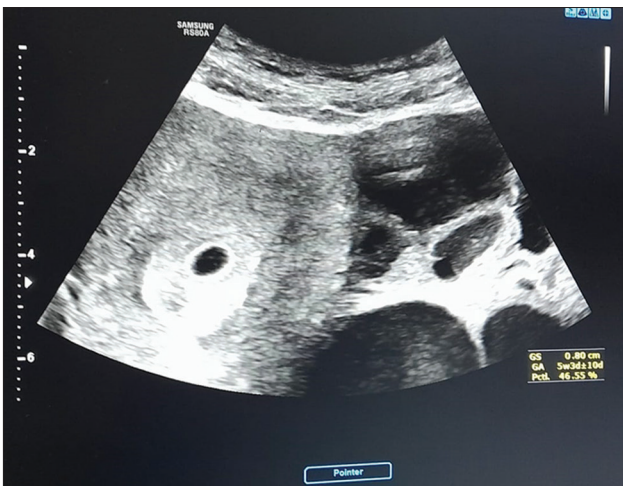
measured 7 × 3.5 × 6.5 cm (145 cc). Moderate ascites with bilateral moderate pleural effusion was also noted. Hence, a diagnosis of spontaneous OHSS was made. Patient was admitted in antenatal ward for supportive therapy along with regular monitoring of vitals, weight. Fluid correction was done with intravenous fluids based on charting. Therapeutic paracentesis and thoracocentesis were done twice to provide symptomatic relief. Thromboprophylaxis with use of Enoxaparin injections (40 mg) was given subcutaneously as per her bodyweight. Since patient was not desirous of this pregnancy, she was undertaken for first trimester medical termination of pregnancy by dilatation and evacuation in view of severe OHSS on day 3 after admission. Post procedure, she was started on cabergoline (0.5 mg) for 8 days in view of its role in reducing neoangiogenesis. Patient was discharged after 10 days on attaining symptomatic relief. Patient was followed up 30 days after procedure with an ultrasound which revealed normal findings in bilateral ovaries with no ascites or pleural effusion.

## Discussion

Since OHSS is typically associated with use of gonadotropins for ovulation induction, its origin in a case of natural pregnancy is largely unknown. Spontaneous



**Figure 1:** Ultrasound image of bulky ovary showing fishnet appearance



**Figure 2:** Ultrasound image of Bulky ovary with intrauterine gestational sac

OHSS usually occurs at 8–14 weeks gestation in contrast to OHSS which occurs at 3–5 weeks of gestation.<sup>[3]</sup> Potential risk factors include young age, low body mass index, history of polycystic ovaries, multiple gestation, and hypothyroidism.<sup>[1]</sup> Due to plethora of potentially life threatening complications, early diagnosis and treatment becomes quintessential. This is possible in cases of OHSS related to its use in treatment of infertility since it can be predicted and managed in time. However, in sOHSS, it is fairly difficult since diagnosis can be done once they are symptomatic. Management of sOHSS is dependent on the stage where early stages can be managed on out patient department basis. But, severe and critical cases,

like in our case, hospital admission with adequate fluid replacement and thromboprophylaxis becomes necessary to avoid complications. A meta-analysis done by Tang *et al.* revealed use of cabergoline to be effective in cases of OHSS since it reduces vascular permeability by inhibiting vascular endothelial growth factor-2 receptor.<sup>[4]</sup>

## Conclusion

Early recognition and timely management of such cases ensures prevention of fatal complications yielding good outcome.

## Declaration

Note: Patient referred to this in case has consented for this publication.

## References

1. Chai W, He H, Li F, Zhang W, He C. Spontaneous ovarian hyperstimulation syndrome in a nonpregnant female patient: a case report and literature review. *J Int Med Res* 2020;48:300060520952647.
2. Liang X, Yu X, Guo X, Wang F. A case report of spontaneous ovarian hyperstimulation syndrome and the long-term management of the endocrine disorder. *Ann Transl Med* 2022;10:384.
3. Pail S, Bagri N, Ghas R. Hypothyroidism induced spontaneous ovarian hyperstimulation syndrome: A rare yet interesting dilemma. *New Indian J OBGYN* 2023;10:229-32.
4. Neha, Chauhan M, Chaudhary D. A rare case on ovarian hyperstimulation syndrome in a spontaneous singleton pregnancy. *Int J Reprod Contracept Obstet Gynecol* 2024;13:1881-4.

## Editor's Note

OHSS is more commonly linked to assisted reproductive technologies, spontaneous OHSS is a rare event reported in 0.2–1.2% cases occurring spontaneously in pregnancy without exogenous hCG use. It can present with abdominal pain, distention, and respiratory symptoms. Early diagnosis is important and crucial for management of the patient, to reduce the maternal mortality rates. The case illustrates the need for awareness among clinicians and the experience of the reporting authors may serve as a guide for similar cases in the future. Management strategies include effective use of supportive therapies, including fluid management and thromboprophylaxis, as well as the novel application of cabergoline in non pregnant patients. In severe cases hospitalization maybe required.

**How to cite this article:** Agrawal A, Gupta P, Mehendale M, Sarmalkar M. A Rare Case of Spontaneous Ovarian Hyperstimulation Syndrome in a Spontaneous Conception with Conservative Management. *MOGS Chronicles* 2024;1(1):13-14.

# Caesarean Myomectomy in a Patient with Multiple Maternal and Fetal Comorbidities: A Rare Interesting Case Report

Zeba H. Pathan, Niranjan N. Chavan, Deepali S. Kapote, Shreya Kampoowale, Ashwini S. Sakhalkar, Rutuja A. Mohite

Department of Obstetrics and Gynecology, LTMMC, Sion, Mumbai, Maharashtra, India

## Abstract

Caesarean myomectomy, traditionally avoided due to fears of complications like haemorrhage and hysterectomy, has been shown to be safe when performed by skilled surgeons with proper haemostatic techniques. In the case of a 36-weeks elderly primigravida with chronic hypertension, polyhydramnios, and multiple fibroids, caesarean myomectomy was successfully performed, demonstrating its safety and effectiveness in a tertiary care setting.

**Keywords:** Fibroid, Pregnancy, Myomectomy, Caesarean myomectomy

**Address for correspondence:** Zeba H. Pathan, Department of Obstetrics and Gynecology, LTMMC, Sion, Mumbai, Maharashtra, India. Phone: +91-9404261803. E-mail: drzebapathan1494@gmail.com

## Introduction

Recent studies suggest that caesarean myomectomy does not increase the risk of haemorrhage or postoperative morbidity when performed by skilled surgeons with proper haemostatic techniques. Common indications include fibroids obstructing the lower uterine segment, complicating uterine closure, preventing necrobiosis, or presenting with an unusual appearance especially pedunculated and anterior wall fibroids.<sup>[1]</sup>

## Case Report

A 38-year-old woman, recently married for the second time and experiencing primary infertility, presented with an abdominal mass to the outpatient department. Upon general examination, there were no significant findings. However, per abdominal examination revealed a firm, mobile mass corresponding to a 16–18 weeks pregnancy size, originating from the pelvis. Per vaginal examination also confirmed a firm, mobile uterus of similar size, with free bilateral adnexa. The patient was advised to undergo ultrasonography and magnetic resonance imaging (MRI) of the pelvis.

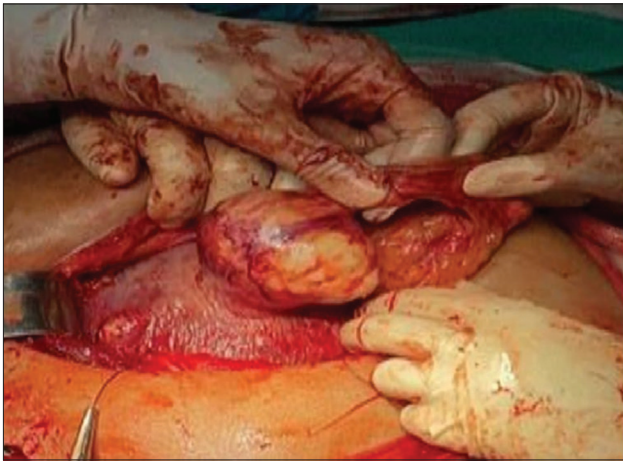
Ultrasonography showed a bulky uterus with multiple small intramural fibroids in the anterior and posterior walls, and a large anterior subserosal fibroid measuring  $5.7 \times 5.1$  cm. MRI findings were consistent with these results and also revealed an incidental intrauterine solid cystic area representing a gestational sac of  $3.2 \times 2.9$  cm. An ultrasound performed at 9 weeks of gestation confirmed the viability of a single intrauterine pregnancy. Despite the risks associated with MRI exposure, the patient, aware of

the potential dangers, chose to continue with the pregnancy due to her history of primary infertility.

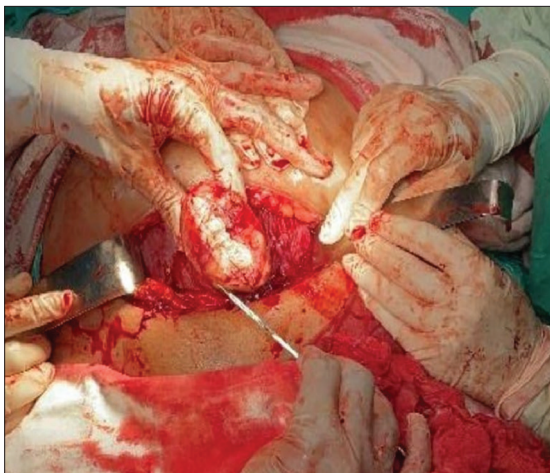
A nuchal translucency scan at 11 weeks and an anomaly scan at 19 weeks both returned normal results. The patient was newly diagnosed with hypertension at 14 weeks and was started on labetalol 100 mg twice daily and ecosprin 150 mg once at bedtime. Routine antenatal care investigations and preeclampsia (PIH) profiles were within normal limits. Additional tests, including an electrocardiogram, 2D echocardiogram, and ultrasound of the kidneys, urinary bladder, and renal artery Doppler, were also normal. Retinoscopy showed no signs of hypertensive changes, and the patient was advised to monitor her blood pressure at home.

In the second trimester, the patient was admitted due to abdominal pain, but torsion and red degeneration of the fibroid were ruled out. An oral glucose tolerance test at 24 weeks returned normal results. At 32 weeks, the patient developed gross polyhydramnios, with the largest amniotic fluid pocket measuring 14.5 cm, although Doppler studies remained normal. She was admitted for safe confinement and received corticosteroid injections of betamethasone 12 mg intramuscularly, 24 h apart, to promote fetal lung maturity. Weekly Doppler scans and PIH profiles were within normal limits, and her blood sugar and blood pressure remained stable.

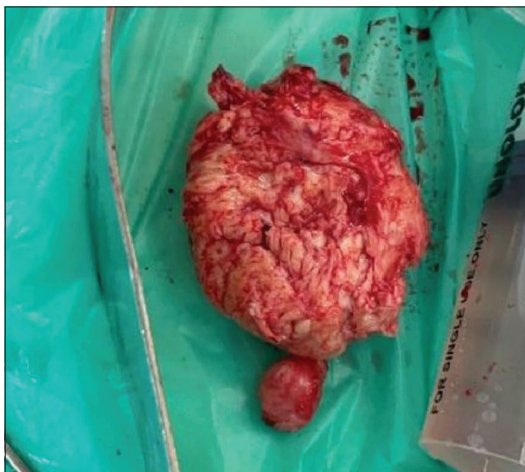At 36 weeks, an elective lower segment caesarean section (LSCS) was performed due to the mother's respiratory distress caused by severe polyhydramnios. A male baby weighing 2.3 kg with an APGAR score of 8/10 was delivered. During the procedure, a caesarean



**Figure 1:** Intraoperative findings of anterior wall subserosal pedunculated fibroid



**Figure 2:** Sutured uterus



**Figure 3:** Resected myoma

myomectomy was performed to remove the anterior wall subserosal pedunculated fibroid [Figure 1] measuring 7 × 6 cm. Vasopressin, diluted to 1:200, was injected into the fibroid until blanching occurred while monitoring the patient's pulse rate. The fibroid was then dissected from the myometrium, and the defect was sutured in

two layers [Figures 2 and 3]. Haemostasis was achieved using several measures, including bilateral uterine artery ligation, oxytocin infusion, intra-myometrial carboprost, tranexamic acid injection, and compression of the raw area with a hot mop.

The estimated blood loss during surgery was 1.2 L, and the patient received one unit of packed red cells intraoperatively. Her postoperative haemoglobin level was 11.3 g/dL. The patient tolerated the procedure and anaesthesia well. Post-delivery, the baby was diagnosed with a tracheoesophageal fistula, which was the likely cause of the gross polyhydramnios and required surgery on the 5<sup>th</sup> day of life.

## Discussion

Sustained estrogen release during pregnancy and breastfeeding is a significant risk factor for the formation of uterine fibroids. These benign tumors affect 20-40% of women during their reproductive years, leading to various complications, including menorrhagia, anaemia, and abdominal pain. If myomectomy could be successfully performed during cesarean deliveries, it would significantly reduce the need for separate surgeries, thereby decreasing patient morbidity and healthcare costs. This approach is particularly advantageous in resource-constrained settings.<sup>[2]</sup>

Additionally, addressing fibroids during cesarean sections can mitigate the risks of complications associated with untreated fibroids, such as torsion or “red” degeneration during subsequent pregnancies. Removing fibroids located in the lower uterine segment not only simplifies surgical procedures but also increases the likelihood of vaginal delivery in future pregnancies. Studies indicate that scar integrity following cesarean myomectomy is superior to that after interval myomectomy, highlighting its safety.<sup>[3]</sup>

## Conclusion

Elective myomectomy after caesarean birth should be approached with caution, and may possibly be limited to individuals with pedunculated fibroids or situations in which the lower segment incision (for retrieving the baby) cannot be closed without removal of the fibroid(s). In order for caesarean myomectomy to be performed on a regular basis, blood banks must be sufficiently staffed and equipped, and their methods must match international standards. Caesarean myomectomy is a safe and effective procedure in a tertiary care centre at the hands of an experienced surgeon.

## Declaration

### Conflict of interest

None.

### Disclosure

None.

## Informed consent

Informed consent was taken from the patient

## References

1. Pathan ZH, Chavan NN, Kampoowale S, Kapote DS, Sakhalkar AS. Caesarean myomectomy in a patient with multiple maternal and fetal comorbidities: A rare interesting case report. *Int J Reprod Contracept Obstet Gynecol* 2022;11:2253-6.
2. Brown D, Fletcher HM, Myrie MO, Reid M. Caesarean myomectomy-A safe procedure. A retrospective case-controlled study. *J Obstet Gynaecol* 1999;19:139-41.
3. Kwawukume EY. Caesarean myomectomy. *Afr J Reproduct Health* 2002;6:38-43.
4. Omar SZ, Sivanesaratnam V, Damodaran P. Large lower segment myoma-myomectomy at lower segment Caesarean section-a report of two cases. *Singapore Med J* 1999;40:109-10.
5. Cobellis G, Messalli EM, Stradella L, Pecori E, Cobellis L. Restitutio ad integrum of myometrium after myomectomy: different results in pregnant and non-pregnant patients. *Minerva Ginecol* 2002; 54:393-5.

## Editor's Note

This case report on caesarean myomectomy highlights an important and often debated surgical approach in obstetrics. By addressing uterine fibroids during caesarean delivery, this technique can alleviate potential complications in future pregnancies and improve maternal health outcomes. With improved surgical techniques this procedure can be now performed safely. The report emphasizes the need for careful patient selection and experienced surgeon to ensure safety and efficacy.

**How to cite this article:** Pathan ZH, Chavan NN, Kapote DS, Kampoowale S, Sakhalkar AS, Mohite RA. Caesarean Myomectomy in a Patient with Multiple Maternal and Fetal Comorbidities: A Rare Interesting Case Report. *MOGS* 2024;1(1):15-17.

# Genitourinary Endometriosis - A Case Report

Jil Kadakia, Shivani Agrawal, Sadhana Desai, Prashant Bhamare

Department of Obstetrics and Gynaecology, Bombay Hospital Institute of Medical Sciences, Mumbai, Maharashtra, India

## Abstract

Urinary tract endometriosis (UTE) is an uncommon but serious manifestation of deep infiltrating endometriosis, carrying the risk of urinary tract obstruction and potential renal dysfunction. We present a case involving a 29-year-old female with cyclic dysuria and dysmenorrhea. This report highlights the diagnosis and surgical management of UTE. Awareness of UTE is crucial for specialists due to its significant health implications. In cases where UTE is identified, a multidisciplinary approach involving both radiological and surgical expertise is essential for optimal patient outcomes.

**Keywords:** Genitourinary endometriosis, bladder nodule, deep infiltrating endometriosis

**Address for correspondence:** Jil Kadakia, Department of Obstetrics and Gynaecology, Bombay Hospital Institute of Medical Sciences, Mumbai, Maharashtra, India. E-mail: jilkadakia506@gmail.com

## Introduction

The identification of endometriosis has been a subject of intense debate over the last decade. Endometriosis is a painful condition that affects up to 10% of women of reproductive age and is characterized by the presence of endometrial glands and stroma, similar to those that line the uterus, growing elsewhere in the body.<sup>[1]</sup> One type of endometriosis is urinary tract endometriosis (UTE). It affects 0.3–12% of all endometriosis patients.<sup>[2]</sup> The urinary system is the second most common site of extrapelvic endometriosis after the gastrointestinal tract (3). The prevalence of disease at specific sites among women with UTE is as follows: bladder, 85%; ureter, 10%; kidney, 4% and urethra, 2%.<sup>[4]</sup>

Although bladder is the most common site of UTE, bladder endometriosis (BE), in general, is rare. In most cases, BE is associated with lower urinary tract symptoms such as frequency and dysuria. Dysuria has been reported in 21–69% of patients with BE and positive correlation was observed between severity and lesion diameter. Presence of cyclical haematuria is considered pathognomic of BE.

## Case Report

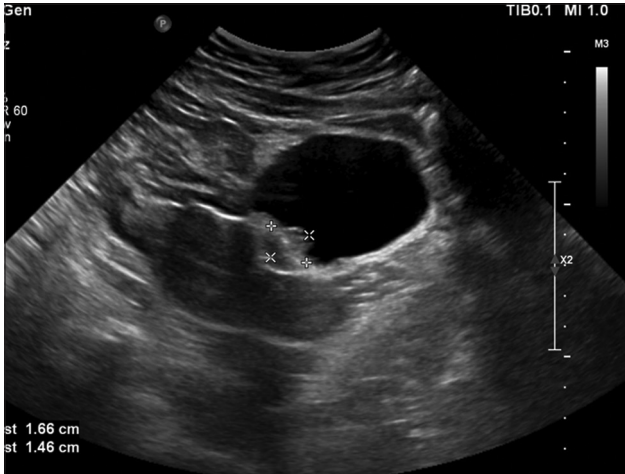A 29-year-old female, P1L1A1, previous 1 lower segment caesarean section, done 6 years ago came with chief complaints of cyclical dysuria and dysmenorrhea which was premenstrual and menstrual since 3 years. No history of haematuria/burning micturition/increased frequency/urgency/urinary incontinence/heavy menstrual bleeding. Cycles were regular with moderate flow. She had been consulting many doctors since then but with unsatisfactory outcomes to various treatments. She had no significant past history. She was taking Tab. Dienogest 2mg since 2019 with no relief in her symptoms.

General examination was within normal limits. Abdominal examination was within normal limits and a well healed Pfannenstiel incision was noted. Pelvic examination was suggestive of a normal sized anteverted uterus with restricted mobility, bilateral fornices were free and non-tender.

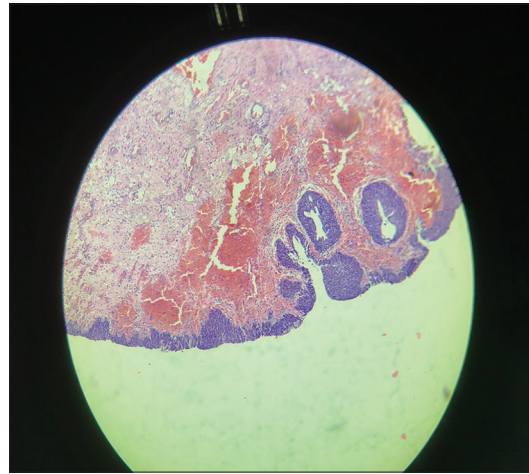
Routine preoperative blood investigations were done. All were within normal limits. Urine routine and microscopy revealed 7–8 red blood cells per high power field and 1–2 pus cells per high power field. CA-125 was 21U.

Lesions were first diagnosed on 3D ultrasonography which appeared irregular and polypoidal of size 14×13×10 mm along posterior wall of bladder and obvious internal vascularity was noted on colour doppler [Figure 1] computed tomography scan revealed hypoechoic thickening at the scar which was adherent to the bladder with echogenic lesion in bladder of 1.4×1.3×1 cm at uterine scar.

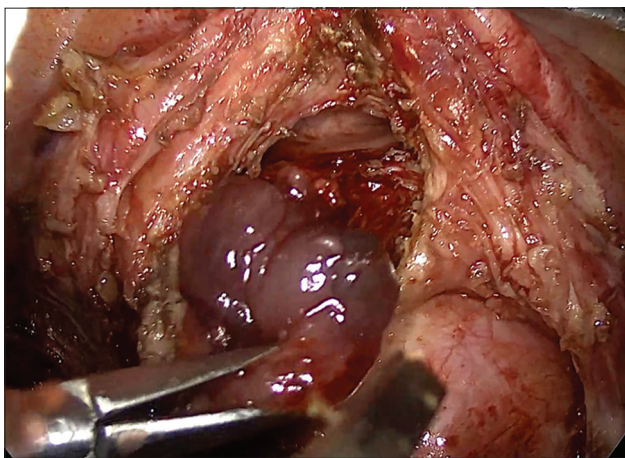
A multidisciplinary team of expert laparoscopic surgeons and urologists were involved. Cystoscopy with laparoscopy was planned. On cystoscopy- evidence of 4×5 mm large papillary broad base nodule near the left ureteric orifice with presence of a blue coloured clot was noted. The lesion was then demarcated using a 26Fr monopolar resectoscope and Collin's knife electrode with 1mm margin. Bilateral ureteric catheterisation was done. Demarcation around the lesion was deepened till full thickness of bladder muscle and lesion margins were confirmed laparoscopically [Figure 2]. Bladder was densely adherent to the lower uterine segment; hence adhesions were carefully separated by blunt and sharp dissection and bladder was mobilised. Endometriotic nodule was excised in full thickness laparoscopically and send for histopathological diagnosis. Bladder was sutured



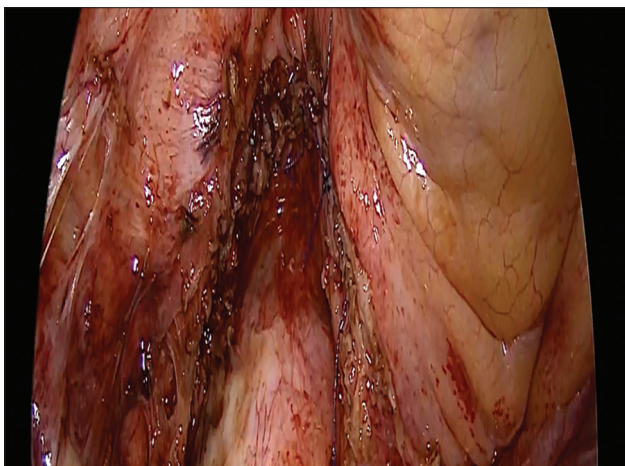
**Figure 1:** 3D ultrasound image of bladder showing nodule on posterior wall



**Figure 4:** Histopathological report image showing endometrial glands and stroma



**Figure 2:** Laparoscopic image of bladder with endometriotic nodule



**Figure 3:** Post bladder closure

with vicryl 3-0 in double layers [Figure 3]. Catheter was removed after 21 days. Antibiotics were given to prevent infection.

Histopathology report demonstrated endometrial glands and stroma consistent with deep infiltrating endometriosis of the bladder [Figure 4]. Patient at 6-month follow-up was symptom free.

## Discussion

Endometriosis is a complex and highly variable disease that still challenges medical practice. It is estimated that UTE affects up to 1% of women with pelvic endometriosis.<sup>[5]</sup> It is increasingly recognized that endometriosis is a multiorgan and systemic inflammatory disease that necessitates interdisciplinary care.

Bladder endometriosis (BE) is defined by the presence of endometriotic tissue invading the detrusor muscle of the bladder. The invasion of the detrusor muscle can be either full thickness or partial thickness.<sup>[6]</sup> BE most commonly develops in the bladder base and bladder dome, rather than in the extra-abdominal bladder.<sup>[7]</sup>

BE can be classified as primary or secondary, depending on its origin. Primary BE occurs spontaneously and may be explained by theories such as retrograde menstruation, coelomic metaplasia, the spread of stem/progenitor cells from the endometrium, or genetic/epigenetic and immune abnormalities. Secondary BE, on the other hand, is iatrogenic, typically developing after pelvic surgeries such as caesarean sections or hysterectomies. Initial evaluation for suspected BE includes a thorough medical history, physical examination, and additional tests, including laboratory evaluations, cystourethroscopy, and imaging techniques.

Differential diagnosis of BE must be known to one during examination, which includes Urinary tract calculus, Urinary tract infection, Intraluminal bladder lesions, Interstitial cystitis, Bladder carcinoma, Amyloidosis. BE is rarely an isolated condition and other forms of endometriosis are frequently concomitant.

Surgical removal of BE nodules is recommended when pain persists despite medical treatment, when the lesion leads to ureteral stricture, or for patients who either cannot undergo hormonal therapy or decline it. The primary objective of the surgery is the complete excision of the bladder nodule.

## Conclusion

In our case, a combination of cystoscopy and laparoscopy allowed complete removal of the endometriotic nodule

while sparing most of the healthy bladder tissue.

However, definitive diagnosis of endometriosis can only be established on histopathological examination.

## Declaration

### Conflict of interest

None.

### Disclosure

None.

### Informed consent

Informed consent Informed consent was taken from the patient.

## References

1. Berveiller P, Ropert S, Mir O, Becker CM, Missmer SA, Zondervan KT. Endometriosis. *N Engl J Med* 2020;383:193-4.
2. Gabriel B, Nassif J, Trompoukis P, Barata S, Wattiez A. Prevalence and management of urinary tract endometriosis: A clinical case series. *Urology* 2011;78:1269-74.
3. Maccagnano C, Pellucchi F, Rocchini L, Ghezzi M, Scattoni V, Montorsi F, *et al.* Ureteral endometriosis: Proposal for a diagnostic and therapeutic algorithm with a review of the literature. *Urol Int* 2013;91:1-9.
4. Berlanda N, Vercellini P, Carmignani L, Aimi G, Amicarelli F, Fedele L. Ureteral and vesical endometriosis. *Obstet Gynecol Surv* 2009;64:830-42.
5. Seracchioli R, Mabrouk M, Montanari G, Manuzzi L, Concetti S, Venturoli S. Conservative laparoscopic management of urinary tract endometriosis (UTE): Surgical outcome and long-term follow-up. *Fertil Steril* 2010;94:856-61.
6. Fedele L, Piazzola E, Raffaelli R, Bianchi S. Bladder endometriosis: Deep infiltrating endometriosis or adenomyosis? *Fertil Steril* 1998;69:972-5.
7. Guerriero S, Condous G, Bosch TV, Valentin L, Leone FP, Van Schoubroeck D, *et al.* Systematic approach to sonographic evaluation of the pelvis in women with suspected endometriosis, including terms, definitions and measurements: A consensus opinion from the International Deep Endometriosis Analysis (IDEA) group. *Ultrasound Obstet Gynecol* 2016;48:318-32.

## Editor's Note

This case report sheds light on the complexities and challenges associated with diagnosing and managing endometriosis, particularly BE which is a type extra pelvic deep infiltrating endometriosis (DIE). It can affect a significant subset of women with endometriosis, and is often misdiagnosed or diagnosed at a late stage, leading to prolonged suffering and ineffective treatments. As clinicians we should be aware regarding the varied presentations of BE and DIE. The involvement of the urinary tract in DIE often complicates management, necessitating a multidisciplinary approach, careful assessment, including advanced imaging, histopathological analysis, to confirm diagnosis and specialized surgical techniques to ensure complete removal while minimizing damage to surrounding structures. Combination of hormonal therapies and surgical options remains the mainstay in managing symptoms and improving quality of life for affected patients.

**How to cite this article:** Kadakia J, Agrawal S, Desai S, Bhamare P. Genitourinary Endometriosis - A Case Report. *MOGS Chronicles* 2024;1(1):18-20.



# Carcinosarcoma in OHVIRA syndrome: an Enigma

Rahat Sayyad<sup>1</sup>, Nozer Sheriar<sup>1</sup>, Nikhil Dharmadhikari<sup>2</sup>, Zubin Sheriar<sup>1</sup>

<sup>1</sup>Department of Obstetrics and Gynecology, Holy Family Hospital, Holy Family Hospital St Andrew's Road, Bandra (West), Mumbai, Maharashtra, India, <sup>2</sup>Department of Surgical Oncology, Faculty of Obstetrics and Gynaecology, Holy Family Hospital, St Andrew's Road, Bandra (West), Mumbai, Maharashtra, India

## Abstract

Malignancies in obstructed hemivagina and ipsilateral renal agenesis are rare, with only six reported cases in literature, all of which have been cervical cancers. A 42 years old, divorced, nulligravida, with a history of Uterus didelphys with a non-communicating horn with hematosalpinx along with ipsilateral renal agenesis with drainage of hematocolpos with marsupialization of hemivagina at the age of 28 years. Presented with persistent mid-menstrual blackish vaginal bleeding. Initial pelvic examination revealed foul-smelling discharge and a mass arising from the cervix. Magnetic resonance imaging pelvis showed a distended vaginal cavity with a large polypoidal mass extending towards the left cervical cavity. Positron emission tomography scan showed a hypermetabolic polypoidal mass arising from the uterine cervix extending into the vagina. Mass which was seen involving the anterior and lateral walls of the cervix was excised. Histopathology report was suggestive of carcinosarcoma of the vagina. A radical hysterectomy with pelvic lymph node dissection was planned. Tumor was inoperable with no discernable plane of dissection extending up to the introitus. The patient is undergoing chemotherapy. This is a rare case of a vaginal carcinosarcoma in a Mullerian anomaly with an aggressive course.

**Keywords:** Herlyn-Werner-Wunderlich syndrome, Obstructed hemivagina and ipsilateral renal agenesis, Vaginal carcinosarcoma, Vaginal malignancy

**Address for correspondence:** Dr. Rahat Sayyad, Holy Family Hospital, Holy Family Hospital St Andrew's Road, Bandra (West), Mumbai, Maharashtra, India. Mobile: +91-8779555401. E-mail: rahat.sayyad@gmail.com

## Introduction

Herlyn-Werner-Wunderlich syndrome also known as obstructed hemivagina and ipsilateral renal agenesis (OHVIRA) syndrome, is a rare congenital anomaly characterized by a triad of Uterus didelphys, obstructed hemivagina and ipsilateral renal anomaly. Malignancies in OHVIRA syndrome are rare with only 6 reported cases in literature, all of which were cervical cancer.

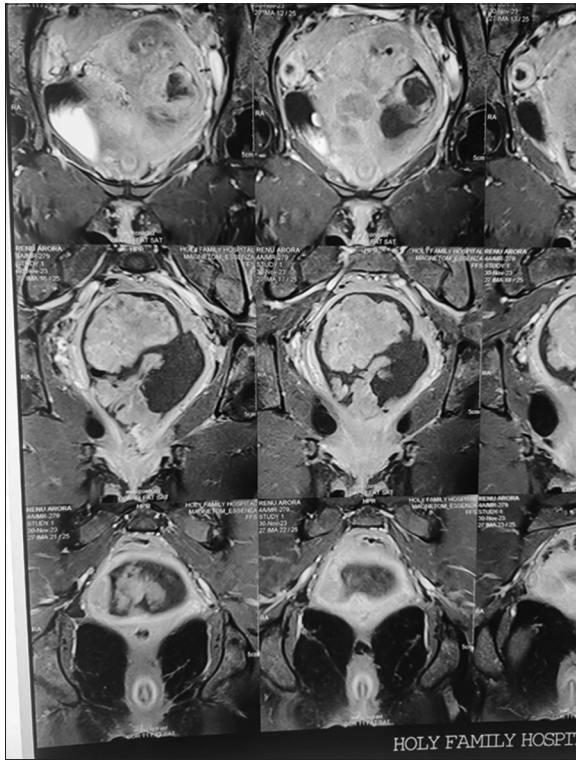
## Case Report

We present a case of a 42 years old divorced, nulligravida, who came with complaints of persistent mid-menstrual blackish vaginal bleeding from last 6 months. At the age of 28 years, she was diagnosed with OHVIRA syndrome i.e. Uterus didelphys with a non-communicating horn with hematosalpinx along with ipsilateral renal agenesis and managed surgically by drainage of hematocolpos with marsupialization of hemivagina. She was a known case of hypothyroidism on treatment. There was no history of cancer in the family.

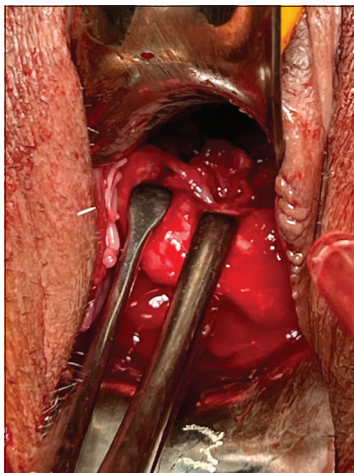
Initial pelvic examination revealed foul-smelling discharge and a mass arising from the cervix. Ultrasound abdomen and pelvis revealed pyometra measuring 8.3 × 8.5 × 5.8 cms ~214 cc seen in endometrial cavity with left kidney. Magnetic resonance imaging [Figure 1] showed a normal sized uterine horn with normal

endometrial stripe with a small anterior wall uterine fibroid. E/o bicollis noted, distended vaginal cavity with large heterogeneous polypoidal mass with heterogeneous post-contrast enhancement. This is seen extending towards the left cervical cavity with presence of vessels in the cranial end. There is beaking seen in upper end of vagina with circumferentially thickened and mildly T2 hyperintense vaginal walls, with possibility of lower vaginal narrowing.

Positron emission tomography scan showed a hypermetabolic polypoidal mass arising from the uterine cervix extending into the vagina. Patient underwent examination under anesthesia with excision of mass which was seen involving the anterior and lateral walls of the cervix and a frozen section was sent which was suggestive of malignancy, s/o possibility of poorly differentiated carcinoma [Figures 2 and 3]. Histopathology reported carcinosarcoma of the vagina. Immunohistochemistry showed the carcinoma component-high grade adenocarcinoma expressing ck, ema, pax8 and p53 (strong diffuse expression mutant expression), ini 1 and p16. The sarcomatous component- high-grade sarcoma with immunoprofile of a homologous high grade stromal sarcoma. The tumor cells express cd10 and cyclin d1 strongly. They are immuno negative for pr, sma, desmin, s-100 protein, cd 34 and ck.



**Figure 1:** Magnetic resonance imaging findings

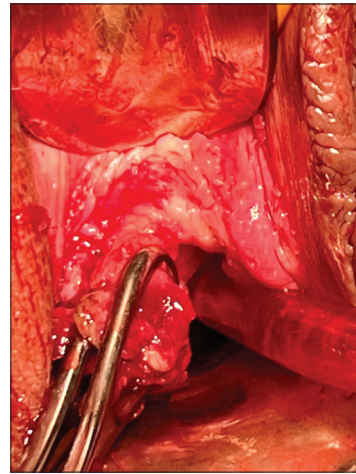


**Figure 2:** Intraoperative findings

A radical hysterectomy with pelvic lymph node dissection was planned for the patient. But during the surgery, tumor was found to be inoperable with no discernable plane of dissection extending up to the introitus showing its aggressive course within a short span of time. As per Federation of Gynecology and Obstetrics Staging for Vaginal Cancer, she had stage III vaginal cancer and T3N1M0 as per TNM staging. The patient underwent chemotherapy with carboplatin but failed to respond. A trial of immunotherapy is being given in the hope of some palliative relief.

## Discussion

Our case is a rare occurrence of vaginal carcinosarcoma in Mullerian anomaly with an aggressive course.



**Figure 3:** Resection of the visible mass

The pathogenesis of OHVIRA syndrome is thought to be a result of the abnormal development of the Wolffian ducts and fusion failure of the Mullerian ducts, which leads to unilateral renal agenesis, imperforated hemivagina, and uterine didelphys and bicollis. The overall prevalence of Mullerian duct abnormality is 2–3%.<sup>[1]</sup>

Many of these present in early infancy because of collection of secretions in the obstructed vagina under influence of maternal hormones; others are picked up within 1–2 years of onset of menarche due to development of hematocolpos, hematometra, or even hematosalpinx. These patients present with cyclical dysmenorrhea, which later evolves into persistent pelvic pain. Very few reports are available regarding OHVIRA syndrome with cancer, particularly uterine cervical cancer.<sup>[2]</sup>

In reported literature, the average age at surgical treatment ranged from 33 to 65 years, with a median age of 43.5 years. Chief complaints included genital bleeding in all cases. Interestingly, all cases of cervical cancer associated with OHVIRA syndrome occurred on the non-visible side of cervix. Carcinosarcomas though rare, representing less than 5% of all uterine tumors,<sup>[3]</sup> account for 16.4% of all deaths caused by a uterine malignancy.<sup>[4]</sup>

## Conclusion

We experienced a case of vaginal cancer involving the anterior and lateral wall of cervix with OHVIRA syndrome, diagnosed as carcinosarcoma, running an aggressive course within the span of 6 months from the onset of symptoms to its diagnosis.

Combining imaging with tissue biopsy is important for women with OHVIRA syndrome who have mid-menstrual bleeding or menorrhagia. The clinician should be aware that in Müllerian anomalies, cervical, vaginal malignancies may be overlooked, delaying the tumor diagnosis thus affecting patient’s reproductive function and quality of life.

## Declaration

### Conflict of interest

None.

### Disclosure

None.

### Informed consent

Informed consent was taken from the patient.

## References

1. Shavell VI, Montgomery SE, Johnson SC, Diamond MP, Berman JM. Complete septate uterus, obstructed hemivagina, and ipsilateral renal anomaly: Pregnancy course complicated by a rare urogenital anomaly. *Arch Gynecol Obstet* 2009;280:449-52.
2. Oka E, Chiyoda T, Iwata T, Yamagami W, Aoki D. Uterine cervical cancer associated with obstructed hemivagina and ipsilateral renal agenesis (OHVIRA) syndrome: A case report and review of the literature. *Gynecol Oncol Rep* 2020;34:100645.
3. Banik T, Halder D, Gupta N, Dey P. Malignant mixed Müllerian tumor of the uterus: Diagnosis of a case by fine-needle aspiration cytology and review of literature. *Diagn Cytopathol* 2012;40:653-7.
4. Bosquet JS, Terstriep SA, Cliby WA, Brown-Jones M, Kaur JS, Podratz KC, *et al.* The impact of multi-modal therapy on survival for uterine carcinosarcomas. *Gynecol Oncol* 2010;116:419-23.

## Editor's Note

This rare case of a high-grade vaginal carcinosarcoma in a case of OHVIRA syndrome, highlights the need for increased awareness among clinicians regarding the potential for malignancies in patients with Müllerian anomalies and the challenges faced in diagnosis and management. Her presentation of persistent mid-menstrual bleeding ultimately led to the discovery of a vaginal carcinosarcoma, a malignancy rarely documented in the context of OHVIRA syndrome. It is pertinent to keep vigilance in patients with Müllerian anomalies, particularly those presenting with atypical symptoms. As the literature on malignancies in OHVIRA syndrome remains limited, this case adds a significant dimension to our understanding. It emphasizes the aggressive nature of the tumor and the importance of early intervention through screening with pap smears, imaging and biopsy protocols.

**How to cite this article:** Sayyad R, Sheriar N, Dharmadhikari N, Sheriar Z. Carcinosarcoma in OHVIRA syndrome: an Enigma. *MOGS Chronicles* 2024;1(1):21-23.

# Hemoperitoneum in a Known Case of Combined Factor V and Factor VIII Deficiency: A Case Report

K. K. Manasa<sup>1</sup>, Himangi S. Warke<sup>1</sup>, Durga D. Valvi<sup>1</sup>, Priyanka B. Rane<sup>1</sup>, Chandrakala Shanmukhaiah<sup>2</sup>

<sup>1</sup>Department of Obstetrics and Gynaecology, Seth G. S. Medical College and KEM Hospital, Parel, Mumbai, Maharashtra, India, <sup>2</sup>Department of Haematology, Seth G. S. Medical College and KEM Hospital, Parel, Mumbai, Maharashtra, India

## Abstract

Factor V and VIII deficiency (F5F8D) is a rare autosomal recessive coagulopathy. We report a case of a 22-year-old nulligravida, who presented with complaints of pain in the lower abdomen. Coagulation profile revealed prolongation of activated partial thromboplastin time (aPTT), prothrombin time (PT), and elevated international normalized ratio (INR). The deficiency of factor V and factor VIII was confirmed with factor test revealing reduced activities of factor V and VIII. Combined deficiency of factors V and VIII should be considered in differential diagnosis of patients with prolonged aPTT, PT and elevated INR. Medical management is reserved for patients presenting with symptoms and signs. The patient was managed conservatively by administration of Factor VIII and Fresh frozen plasma.

**Keywords:** Factor V deficiency, Factor VIII deficiency, F5F8D

Address for correspondence: Dr. K. K. Manasa, Department of Obstetrics and Gynaecology, Seth G. S. Medical College and KEM Hospital, Parel, Mumbai, Maharashtra, India. Phone: +91-7012721426. E-mail: manasamohan990@gmail.com

## Introduction

The combined factor V and factor VIII deficiency (F5F8D) is a relatively uncommon autosomal recessive constitutional haematological disorder.<sup>[1]</sup> The condition was first identified in 1954 by Oeri *et al.* The estimated prevalence is 1 in 100,000. The frequency of such disorders increases 8–10-fold with consanguinity. Easy bruising, epistaxis, menorrhagia, gum bleeding, and soft-tissue bleeding are some of the common presenting symptoms. Bleeding time and platelet count are normal while aPTT and PT are prolonged and INR is elevated. To reach a diagnosis, further factor testing and advanced genetic analysis needs to be performed. Successful management to prevent bleeding from surgical procedure includes the administration of specific factor and fresh frozen plasma.

## Case Presentation

This was a case of a 22-year-old female, married for one year with known factor V and factor VIII deficiency (F5F8D) presenting with pain in abdomen for 4 days, dull aching, continuous, non-radiating in nature. She did not have any bowel or menstrual complaints. She was detected with combined factor V and factor VIII deficiency at age of 5 years following an episode of prolonged bleeding at injury site on left upper limb following an accidental fall. She had multiple hospital admissions for heavy menstrual bleeding with multiple FFP and factor VIII transfusions and was started on combined oral contraceptive pills for the same.

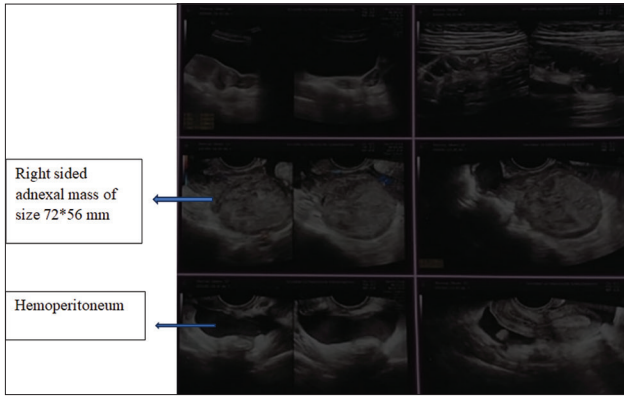
At presentation in emergency patient was vitally stable, abdomen was soft with no guarding, tenderness. On vaginal examination uterus was normal size, deviated to left side with mass in right fornix about 6\*6 cm, firm to cystic in consistency, non-tender. The mass was felt separate from

the uterus with restricted mobility. There was no cervical motion tenderness. Left fornix free and non-tender. Urine pregnancy test was negative.

At 5 years of age the patient was diagnosed to have combined Factor V and Factor VIII Deficiency, with laboratory parameters of PT, 22.5(control-12.9) and aPTT, 78.8(control-28.6). Factor assay revealed a value of Factor VIII to be 2.2% of normal pooled plasma (NR-50-150%) and Factor V to be 2.6% of normal pooled plasma (NR-50-150%).

Blood investigations at presentation with abdominal pain were Hb of 9.1 g%, WBC of 9500 cells/mm<sup>3</sup>, Platelet 2.02 lakhs, prothrombin time (PT) 20.55 (control- 13.7), INR 1.64, Fib-449.14 (Normal range 200-400 mg/dL), with D Dimer value of 1.10mg/L (Normal range <1.7 mg/dl). Ultrasound was suggestive of a right adnexal mass measuring 72\*56 mm with minimal hemoperitoneum [Figure 1]. A clinical diagnosis of right adnexal mass with hemoperitoneum in a known case of combined factor V and factor VIII deficiency was made.

She was managed conservatively with factor VIII and FFP transfusions. Management included monitoring of her vital parameters, abdominal girth, blood parameters and ultrasound at serial intervals. Factor VIII transfusion of 1250IU for 4 days was given with the dose calculation according to the body weight and nature of bleeding by hematologist. Factor 5 correction was given by 4 FFP transfusions on admission. Injection tranexamic acid 1 g thrice daily for 2 days was given followed by tablet tranexamic acid 500 mg thrice daily for 7 days to prevent further bleeding. Cyclical combined oral contraceptives pills started. Patient was discharged on day 5 following admission when she was hemodynamically stable and had no complaints.



**Figure 1:** Trans abdominal sonography showing right adnexal mass with hemoperitoneum

On discharge her Hb was 9.2 g %, WBC was 8440 cells/mm<sup>3</sup>, Platelets were 1.6 Lakhs. PT was 16.6 (control-13.8), INR was 1.5. Factor assay done at the time of discharge revealed a value of Factor VIII -18% of normal pooled plasma (NR - 50–150%) and Factor V - 60% of normal pooled plasma (NR - 50–150%). Follow up ultrasound after 3 months revealed reduction in size of adnexal mass to 43\*35mm.

## Discussion

The combined Factor V and Factor VIII deficiency (F5F8D) disorder results from gene mutations in either two genes LMAN1 (chromosome 18; 18q21) or MCFD2 (chromosome 2; 2p21).<sup>[2]</sup> The two genes produce the ERGIC-53/MCFD2 protein complex, which serves as a cargo receptor, transporting coagulation factors V and VIII to the Golgi apparatus. LMAN1 mutations explain around 70% of cases and solely comprise null mutations.<sup>[3]</sup> MCFD2 mutations occur in about 30% of cases and include both null and missense variants.<sup>[4]</sup>

Normal levels of Factor V and factor VIII levels should be between 50% and 150%. Symptoms like epistaxis, menorrhagia, easy bruising, bleeding following trauma or surgery, and to a lesser extent, hemarthrosis and muscle hematomas are the most prevalent.<sup>[5]</sup> Replacement of the factors is the treatment, though regular prophylaxis is not necessary, Prophylaxis should be considered in situations of recurrent hemarthrosis or intramuscular haemorrhage. FFP regimen can effectively limit bleeding during tooth extractions, circumcision, and labour preparation. The overall prognosis for mild illness is good. Severe variety of the disease should be treated at tertiary care centres along with haematologists.

## Conclusion

The Factor V and factor VIII deficiency is more prevalent in areas where consanguinity is common. The disorder should be suspected in any patient with prolonged aPTT, PT and elevated INR. Management in form of regular replacement with FFP and Factor concentrates is reserved for recurrent severe bleeding.

© The Author(s). 2024 Open Access. This article is distributed under the terms of the Creative Commons Attribution 4.0 International License (<https://creativecommons.org/licenses/by-nc/4.0/>), which permits unrestricted use, distribution, and non-commercial reproduction in any medium, provided you give appropriate credit to the original author(s) and the source, provide a link to the Creative Commons license, and indicate if changes were made. The Creative Commons Public Domain Dedication waiver (<http://creativecommons.org/publicdomain/zero/1.0/>) applies to the data made available in this article, unless otherwise stated.

## Declaration

### Disclosures Human subjects

Consent for the use of case details taken from the patient.

### Conflicts of interest

None.

In compliance with the ICMJE uniform disclosure form, all authors declare the following: Payment/services info: All authors have declared that no financial support was received from any organization for the submitted work.

Financial relationships: All authors have declared that they have no financial relationships at present or within the previous three years with any organizations that might have an interest in the submitted work.

## References

- Zheng C, Zhang B. Combined deficiency of coagulation factors V and VIII: An update. *Semin Thromb Hemost* 2013;39:613-20.
- Zhang B, Spreafico M, Zheng C, Yang A, Platzer P, Callaghan MU, *et al.* Genotype-phenotype correlation in combined deficiency of factor V and factor VIII. *Blood* 2008;111:5592-600.
- Alsheikh S, Alghamdi R, Alqatari A, Alfareed A, AlSaleh M. Combined factor V and VIII deficiency with LMAN1 mutation: A report of 3 Saudi siblings. *Am J Case Rep* 2022;23:e937312.
- Ivaskevicius V, Windyga J, Baran B, Bykowska K, Daugela L, Watzka M, *et al.* The first case of combined coagulation factor V and coagulation factor VIII deficiency in Poland due to a novel p.Tyr135Asn missense mutation in the MCFD2 gene. *Blood Coagul Fibrinolysis* 2008;19:531-4.
- Peyvandi F, Tuddenham EG, Akhtari AM, Lak M, Mannucci PM. Bleeding symptoms in 27 Iranian patients with the combined deficiency of factor V and factor VIII. *Br J Haematol* 1998;100:773-6.

## Editor's Note

A combined Factor V and Factor VIII deficiency (F5F8D) is extremely rare genetic disorder with prevalence of 1:1,000,000 in the general population. This disorder is common in areas where consanguinity is more prevalent. This case report highlights the complexities of this autosomal recessive disorder and sheds light on the challenges faced by individuals living with it, particularly concerning bleeding management and the need for specialized care. A high index of suspicion should be kept for patient with prolonged aPTT, PT and elevated INR. Management strategy involves a multidisciplinary approach with conjunction with haematologist, replacing the factors and FFP to prevent bleeding from surgical procedure. Antiplatelets and COC can be considered in cases of heavy menstrual bleeding in these cases.

**How to cite this article:** Manasa KK, Warke HS, Valvi DD, Rane PB, Shanmukhaiah C. Hemoperitoneum in a Known Case of Combined Factor V and Factor VIII Deficiency: A Case Report. *MOGS Chronicles* 2024;1(1):24-25.

# Genital Herpes by Herpes Simplex Virus 1 in a Postmenopausal Woman: A Case Report

Neena Patwardhan

Department of Obstetrics and Gynecology, Bhatia Hospital, Tardeo Road, Grant Road West, Mumbai 400 007, Mumbai, Maharashtra, India

## Abstract

Herpes simplex virus (HSV-1) affects 3.7 billion people under the age 50 years across the world as per World Health Organisation in 2016. HSV-1 most often causes infection in mouth and lips, called cold sores. It is highly contagious and can spread to genital area during oral sex and by genital touching. Genital herpes is more common in women than men. It is mainly because the mucosal lining of the female external genitalia is likely to be more vulnerable than the thin but keratinised skin of male genitalia. One in five women between ages 14–50 years has genital herpes. The first signs of genital herpes usually show up in 2–12 days after having sexual contact with someone who has herpes. It is a treatable sexually transmitted infections (STI), but the virus stays inside the body and becomes active from time to time. So genital herpes is a life-long disease. People should practice protected sex and undergo screenings for STI.

**Keywords:** Genital herpes, Herpes simplex virus-1 infection, Sexually transmitted infection

**Address for correspondence:** Neena Patwardhan, Department of Obstetrics and Gynecology, Bhatia Hospital, Tardeo Road, Grant Road West, Mumbai 400 007, Mumbai, Maharashtra, India. Mobile: +91-9820482136. E-mail: drneenapatwardhan@gmail.com

## Introduction

Herpes simplex virus (HSV-1) infection has been commonly detected cause of genital herpes in oral genital sex practice. Several studies have shown that the relative proportion of genital HSV-1 isolates has increased even more strikingly in past two decades due to increase in oral- genital contact.<sup>[1]</sup>

Genital HSV-1, which almost always causes a true primary infection, is more likely to be severe during the initial episode. However, genital HSV-1 causes fewer recurrences (few or none after the 1<sup>st</sup> year of infection) and is shed asymptomatically infrequently.<sup>[2]</sup>

## Case Report

A 50 years old post- menopausal lady (menopausal since 2 years) had complaints of burning sensation in vagina after micturition, vaginal discharge accompanied by low grade fever, weakness, throbbing headache, flu like symptoms since 2 days. She had a history of international travel where she had sexual contact with partner 10 days ago. Her partner had past history of cold sores on his lips around 10 years ago. Currently he was asymptomatic. She was consuming micro and macro nutrient supplements but stopped since 1 month.

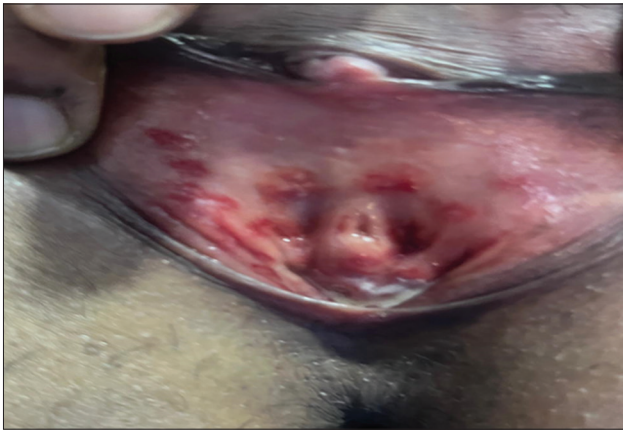
On per speculum examination, cervix looked congested. There was minimal non-foul smelling white discharge and multiple ulcerative lesions around urinary meatus just inside labia minora and in anterior vaginal wall [Figure 1].

Human immunodeficiency virus (HIV), venereal disease research laboratory (VDRL) and liquid based cytology (LBC) Pap smear with human papillomavirus (HPV) DNA and for genital tract infections namely HSV 1/2, trichomonas vaginalis, ureaplasma urealitycum,

mycoplasma genitalium, N. gonorrhoeae and chlamydia trachomatis was done. The lab reports showed positive for HSV-1 virus. The rest all were negative. Her male partner underwent blood tests for all sexually transmitted infections (STI), HIV, VDRL. His HSV-1 immunoglobulin G (IgG) was positive, HSV-1 IgM negative. All other blood reports were negative. Her LBC Pap report showed inflammatory smear with no cytopathic changes of HSV in the cells of cervix, negative for intraepithelial lesion or malignancy. HPV negative. The patient's HSV-1 IgM and IgG were negative. She was given Tab Valacyclovir (500 mg) twice daily for 10 days along with multivitamin multimineral tablets and local gel to apply on the lesions. Her ulcerative lesions improved remarkably in 10 days and she became asymptomatic soon. Reference from a Dermatologist taken for her and partner. The Dermatologist prescribed Tab Valacyclovir (500 mg) twice daily for 3 months for her male partner. She was given a maintenance dose of tab Valacyclovir (500 mg) OD for 10 more days.

## Discussion

HSV-1 can be found in body fluids, enter the body through mucous membranes or skin abrasions. The first outbreak appears as blisters in vagina in 2–12 days after having sexual contact with someone who has or had HSV-1 infection in the past, particularly when immunity is low. The blisters may become ulcerative and ooze fluid. The viral infection may cause headache, bodyache and fever. Antiviral drugs taken at the first sign speed up the healing of sores and help to reduce the symptoms. However, it is important to know that HSV can be passed to another person even when symptoms are absent. To reduce the chances of transmitting HSV to a partner, use barrier



**Figure 1:** Multiple ulcers inside labia minora around urinary meatus

methods such as condoms and dental dams during all sexual activity. The virus stays dormant within the body until low immunity (stress, sickness) triggers an outbreak. However, even in dormant period, it is possible to transmit HSV to a partner. There is currently no cure for genital herpes, but researchers are working on developing a vaccine.

## Conclusion

Genital herpes is more common in women than men, with an incidence of one in five women between ages 14 to 50 years. It is a treatable STI, but the virus stays inside the body and becomes active from time to time, making it a life-long disease. Awareness and education about safe sex and screenings methods for sexually transmitted infections should be given to the patients to prevent it.

## Declaration

### Conflict of interest

None.

## Disclosure

None.

## Informed consent

Informed consent was taken from the patient.

## References

1. Roberts CM, Pfister JR, Spear SJ. Increasing proportion of herpes simplex virus type 1 as a cause of genital herpes infection in college students. *Sex Transm Dis* 2003;30:797-800.
2. Engelberg R, Carrell D, Krantz E, Corey L, Wald A. Natural history of genital herpes simplex virus type 1 infection. *Sex Transm Dis* 2003;30:174-7.

## Editor's Note

This case report highlights the increasing prevalence of genital HSV-1 infections. It is important for the clinician to take a detailed history of sexual contact, do a thorough diagnostic assessment to identify the causative agent of genital ulcers. It also underscores the need for appropriate treatment protocols. The use of antiviral therapy, such as Valacyclovir, within 3 days of the outbreak, has proven effective in managing acute outbreaks and preventing recurrences. Research continues to advance towards more effective methods like the development of a vaccine. Since genital herpes is a life long condition, prevention is the key. Patient education regarding the asymptomatic transmission of HSV-1 and the importance of using barrier methods to reduce the risk of transmission to partners remains crucial in prevention of this infection.

**How to cite this article:** Patwardhan N. Genital Herpes by Herpes Simplex Virus 1 in a Postmenopausal Woman: A Case Report. *MOGS* 2024;1(1):26-27.

# Save the Uterus! A Case of Large Fibroid with Infertility

Krutika Ramdin, Reena Wani

Department of Obstetrics and Gynecology, Dr. R. N. Cooper Hospital, Juhu, Mumbai, Maharashtra, India

## Abstract

The occurrence of gynaecologic cancers during pregnancy is rare, affecting approximately 4 to 8 in 100,000 pregnancies. Among these, ovarian cancer is the second most common, complicating 1 in 15,000 to 32,000 pregnancies. We present a case of a 34-year-old primigravida diagnosed with advanced ovarian adenocarcinoma during her third trimester. Initial ultrasound revealed a large complex mass, and subsequent biopsy confirmed adenocarcinoma. A multidisciplinary approach led to six cycles of neoadjuvant chemotherapy with Carboplatin and Paclitaxel, significantly improving fetal conditions. An elective caesarean section at 36 weeks resulted in the delivery of a healthy baby. Following surgery, histopathological examination confirmed bilateral ovarian adenocarcinoma. The patient underwent additional chemotherapy and cytoreductive surgery with hyperthermic intraperitoneal chemotherapy (HIPEC). After nine cycles of adjuvant chemotherapy, follow-up scans indicated no recurrence. This case highlights the importance of a coordinated multidisciplinary approach in managing ovarian cancer during pregnancy, emphasizing timely interventions to optimize maternal and fetal outcomes.

**Keywords:** Fibroid, Leiomyoma, Cystic degeneration, Hydro dissection

Address for correspondence: Krutika Ramdin, Department of Obstetrics and Gynecology, Dr. R. N. Cooper Hospital, Juhu, Mumbai, Maharashtra, India. Mobile: +91-7506732966. E-mail: drkrutikaramdin1@gmail.com

## Introduction

Uterine smooth-muscle tumors (leiomyomas or myomas), with a prevalence rate of up to 70%, are the most common benign uterine tumors in women during their reproductive years.<sup>[1]</sup>

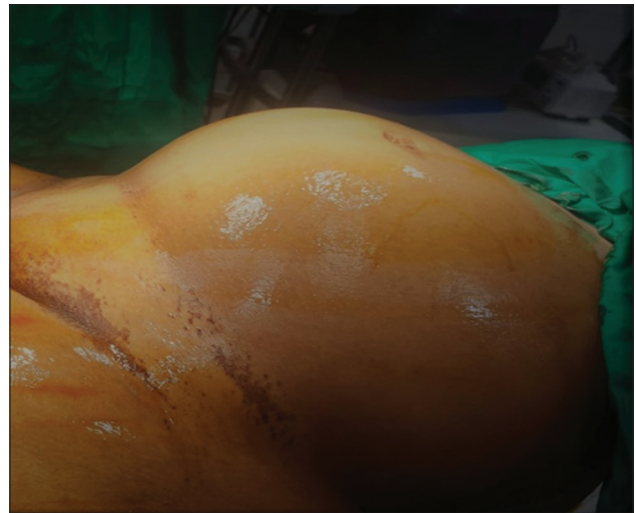Although they are benign and can be asymptomatic, around 30% of fibroids cause profuse menstrual bleeding, irregular uterine bleeding, pelvic discomfort and pain due to pressure on adjacent organs and structures, obstetric complications such as infertility, recurrent abortions or preterm labour.<sup>[2]</sup>

While hysterectomy is the primary indication for this pathology, considering age of incidence and related symptoms, for the fertile age population, the preferred surgical intervention is myoma removal with uterine preservation.<sup>[3]</sup>

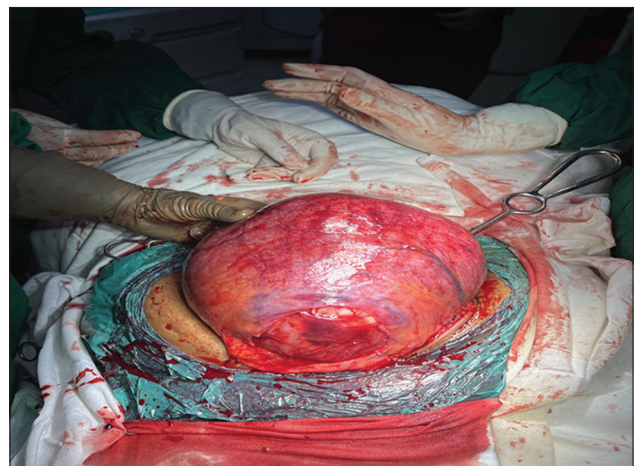
## Case Report

Discussing about the dilemmas and difficulties faced in a case of 37 years old, with history of two abortions (POA2), married since 15 years with secondary infertility presented with complaints of palpable abdominal mass and heavy menstrual flow.

On per abdomen examination uterus was almost 30–32 week of size, non-tender, ballotable, side to side mobility was present [Figure 1]. On per speculum examination cervix was deviated to right side. On per vaginal examination uterus was around 30–32 weeks, anteverted, bilateral fornices were free and non tender, Hingorani's sign was negative. On ultrasonography transabdominal and MRI was suggestive of  $18.6 \times 13 \times$

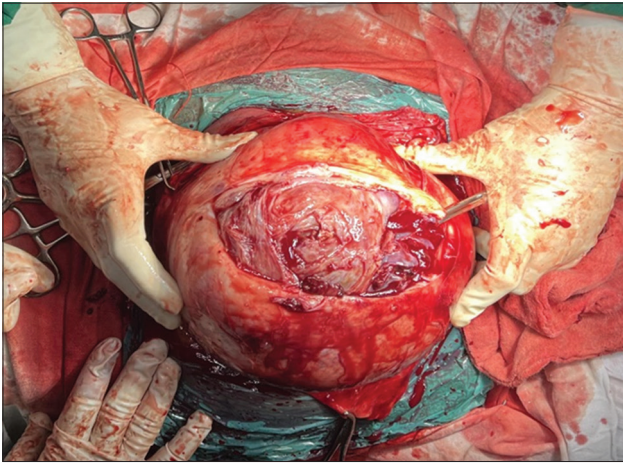


**Figure 1:** Pre-operative image of abdomen with myoma

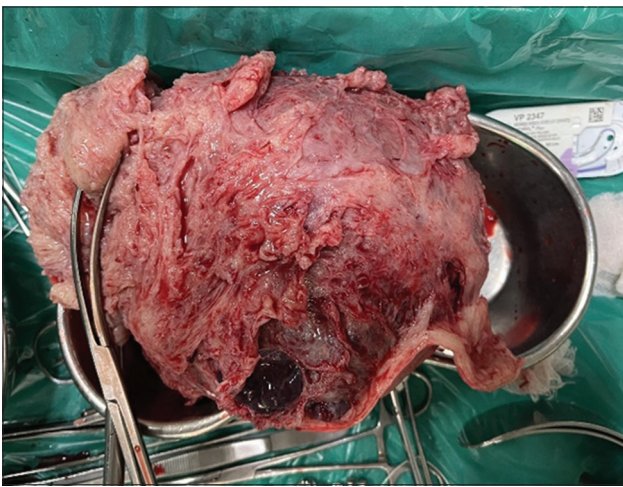


**Figure 2:** Intraoperative Single myoma of size 30–32 weeks

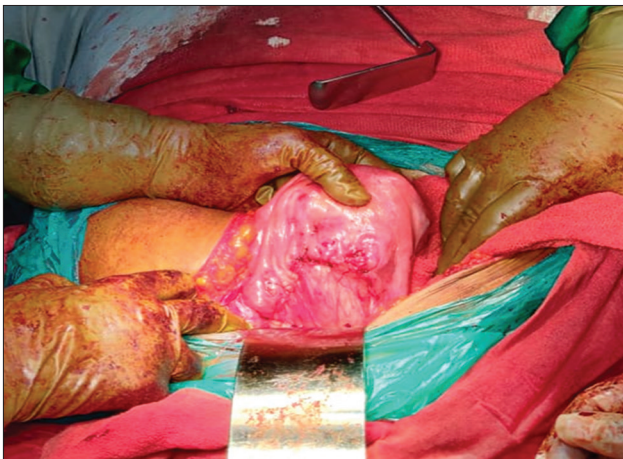



**Figure 3:** Uterus with myoma around 18–15 cm extending from anterior wall down to cervix, with uterus pushed posteriorly



**Figure 4:** Dissected myoma



**Figure 5:** Reconstruction of uterus post myomectomy

18.6 cm size subserosal fibroid with cystic degeneration with pressure effects on distal right ureter and resulting in right hydronephrosis and hydroureter. Single fibroid of

size 30–32 weeks extending from anterior wall down to cervix, with uterus pushed posterior.

We faced different difficulties such as to consider myomectomy or hysterectomy, the approach of the procedure via laparoscopy or exploratory, risk of recurrence of the fibroid and prognosis with the aspect of future pregnancies

In the pre-operative management detailed history of the patient was taken with proper counselling of the patient for the need of sos hysterectomy, optimization of hemoglobin preoperatively and detailed pre-anaesthetic workup was done. Patient underwent an open myomectomy [Figures 2 and 3]. Intra operative management included use of Vasopressin to minimize the blood loss, use of elliptical incision for proper dissection, use of hydro dissection, principles of myomectomy, use of hypotensive anaesthesia, surgical technique such as triple tourniquet technique and proper closure of dead space were used [Figures 4 and 5].

## Discussion

With the correct method of dissection and steps of myomectomy, we managed to save the uterus in a case of secundar infertility. The patient required one pint of whole blood and was discharged on post operative day 4.

Various techniques such as use of GnRh analogues pre-operatively to reduce the blood loss,<sup>[4]</sup> pre-operatively use of interventions on uterine arteries such as laparoscopic uterine artery dissection, uterine artery embolization,<sup>[5]</sup> intraoperatively use of intra-fibroid infiltration of vasopressin, intravaginal misoprostol or dinoprostone, the use of pro-fibrin/thrombin agents, surgically we can use the single tourniquet technique which is generally used entails the application of the tourniquet around the cervix to occlude both uterine arteries or the triple technique which involves the occlusion of the ovarian vessels as well. Use of pharmacologic agents for manipulation of the coagulation cascade with antifibrinolytic agents such tranexamic acid, aprotinin, aminocaproic acid also helps in the management of such cases.

## Conclusion

By utilizing advanced surgical techniques and careful pre-operative planning, we effectively addressed the complications associated with the fibroid, including hydronephrosis. This approach not only alleviated the patient's symptoms but also maintained her reproductive potential, emphasizing the importance of individualized care in managing uterine myomas in reproductive age women.

## Declaration

### Conflict of interest

None.

## Disclosure

None.

## Informed consent

Informed consent was taken from the patient.

## References

1. Giuliani E, As-Sanie S, Marsh EE. Epidemiology and management of uterine fibroids. *Int J Gynaecol Obstet* 2020;149:3-9.
2. Micić J, Macura M, Andjić M, Ivanović K, Dotlić J, Micić DD, *et al*. Currently available treatment modalities for uterine fibroids. *Medicina* 2024b;60:868.
3. Cianci S, Gulino FA, Palmara V, La Verde M, Ronsini C, Romeo P, *et al*. Exploring surgical strategies for uterine fibroid treatment: A comprehensive review of literature on open and minimally invasive approaches. *Medicina* 2023;60:64.
4. Angioni S, D'Alterio MN, Daniilidis A. Highlights on medical treatment of uterine fibroids. *Curr Pharm Des* 2021;27:3821-32.
5. Peng Y, Cheng J, Zang C, Chen X, Wang J. Comparison of laparoscopic myomectomy with and without uterine artery occlusion in treatment of symptomatic multiple myomas. *Int J Gen Med* 2021;14:1719-25.

## Editor's Note

Large symptomatic fibroids in reproductive age women pose a significant challenge in management. subserosal This case highlights the dilemma faced in balancing the need for effective treatment while preserving reproductive potential. The thorough pre-operative assessment and joint decision with the patient and family is essential in tailoring the best approach to surgical intervention. Fibroid mapping preoperatively with a 2D or 3D ultrasound preoperatively can help plan the surgery. Utilizing advanced techniques, such as vasopressin infiltration and meticulous dissection, the surgical team, helps to minimize blood loss and optimize patient outcomes. Preoperatively GnRh can help reduce the size of the fibroid.

**How to cite this article:** Ramdin K, Wani R. Save the Uterus! (Case of Large Fibroid with Infertility). *MOGS Chronicles* 2024;1(1):28-30.



# MOGS CHRONICLES

## INSTRUCTIONS FOR AUTHORS



Before submission read instructions carefully.  
Submissions not complying to the requirements will not be considered.

### General Instructions

1. Last date for submission of your case report: Jan 20, 2025
2. Case report of not more than 500 words (Word limit exclusive of the text in the title page, abstract, references, tables and figures)
3. Maximum 4 photos and not more than 5 latest references, less than 5 years old
4. The person who begins the manuscript submission process is by default the Corresponding Author
5. Declaration of conflict of interest. Senior author from all the co-authors should attest. All authors to be involved in the management of the case
6. Patient consent must be taken and submitted along with the report.
7. Send in your manuscript and necessary documents to [mogschronicles24@gmail.com](mailto:mogschronicles24@gmail.com) and CC to: [mogs2012@gmail.com](mailto:mogs2012@gmail.com)
8. Submissions not complying to the above instructions and incomplete documents can be rejected.
9. Final decision of acceptance lies with MOGS and editors.
10. Accepted manuscripts will be intimated by email.

### Guidelines for submission

1. Cover letter
2. Title page: Should include: Title of the article. For all contributing authors provide- Full names, departmental and institutional affiliation, e-mail address, telephone numbers, including the city, state or province, and country where the work was performed. Colour photograph of the First author and a 100 words description of the author written in third person.
3. Abstract: Unstructured 200 words case summary
4. Minimum 3 keywords.
5. Text: Manuscripts should be submitted in Word. Use a normal, plain font (e.g., 10-point Times Roman) for text.
6. Please type references double-spaced and number them in order of their first appearance in the text (maximum 5 and less than 5 years old). Once a reference is cited, all subsequent citations should be to the original number.
7. Patient consent to be taken and a note made in the manuscript. [Click here](#) to download **Patient consent** for publication form.
8. Figures: Maximum 4 high quality photos (related to the case) to be submitted separately than text as attachments in the email. The figures should be properly labeled and indicated in the manuscript. If you include images that have already been published elsewhere, you must obtain permission for both the print and online format.
9. Authorship and Disclosure Form to be signed by the Senior author or Head of Department.

[Click here](#) to download Authorship and Disclosure form

**\*Note:** This publication is meant for internal circulation and not an indexed journal. This report will not amount to a journal publication.

## Types of Papers

- Case report of not more than 500 words (Word limit exclusive of the text in the title page, abstract, references, tables and figures).

## Important Notes

- Word limits of all articles are exclusive of the text in the title page, abstract, references, tables and figures.
- All submissions will be subjected to the review process of the journal.

Submission of a manuscript implies: that the work described has not been published before; that it is not under consideration for publication anywhere else; that its publication has been approved by all co-authors, if any, as well as by the responsible authorities tacitly or explicitly – at the institute where the work has been carried out. The publisher will not be held legally responsible should there be any claims for compensation.

## Permissions

Authors wishing to include figures, tables, or text passages that have already been published elsewhere are required to obtain permission from the copyright owner(s) for both the print and online format and to include evidence that such permission has been granted when submitting their papers. Any material received without such evidence will be assumed to originate from the authors. Please ensure you provide all relevant editable source files. Failing to submit these source files might cause unnecessary delays in the review and production process.

## Copyright

Copyright on all accepted manuscripts will be held by The Mumbai Obstetrics and Gynaecological Society (MOGS). It is mandatory that the Copyright / Authorship / Disclosure Form is signed by all the authors, expressly transferring copyright to the MOGS in the event the manuscript is accepted for publication. This form must be submitted along with the manuscript on the Email: [mogs2012@gmail.com](mailto:mogs2012@gmail.com). The form can be downloaded from the hyperlink on the right side of the screen. Manuscripts without this form will not be considered for publication.

## Compliance with Ethical Standards

To ensure objectivity and transparency in research and to ensure that accepted principles of ethical and professional conduct have been followed, authors should include information regarding sources of funding, potential conflicts of interest (financial or non-financial), informed consent if the research involved human participants, and a statement on welfare of animals if the research involved animals.

Authors should include the following statements (if applicable) in a separate section entitled “Compliance with Ethical Standards” when submitting a paper:

- Disclosure of potential conflicts of interest
- Research involving Human Participants and/or Animals
- Informed consent

Please note that standards could vary slightly per journal dependent on their peer review policies (i.e. single- or double-blind peer review) as well as per journal subject discipline. Before submitting your article check the instructions following this section carefully. The corresponding author should be prepared to collect documentation of compliance with ethical standards and send if requested during peer review or after publication.

The Editors reserve the right to reject manuscripts that do not comply with the above-mentioned guidelines. The author will be held responsible for false statements or failure to fulfill the above-mentioned guidelines.

# AICOG 2025

MUMBAI

67th All India Congress of Obstetrics & Gynaecology

8 - 12 January, 2025 | Jio World Convention Centre

## DAY WISE CONFERENCE PROGRAM

08

January, 2025

- 21 Pre-Conference Workshops
- FOGSI Managing Committee Meeting
- AICOG has Talent

09

January, 2025

- CG Saraiya CME
- 9 FOGSI Committee Workshops
- FOGSI JOGI PICSEP Workshop
- Inauguration
- Inaugural Function & Cultural Program with Celebrities & Fashion Walk for GENDER EQUALITY

10

January, 2025

- Dr. Rishma Pai & Dr. Hrishikesh Pai Badlaav Oration - Orator: Dr. Frank Louwen (President Elect - FIGO)
- Dr. S Shantha Kumari Dheera Oration - Orator: Dr. Diane Francoeur (CEO - Canadian Society)
- FOGSI Amadeus Shreya Oration - Orator: Dr. Raneer Thakar (President - RCOG)
- "Shoonyam Musical Concert " by Shri Rohit Arora and Music Director Mr. Abhishek Ray
- Dinner & Cultural Night with Celebrities & India's Top Singer - SONU NIGAM promoting "ANAEMIA MUKT BHARAT"

11

January, 2025

- Dr. Nandita Palshetkar "We for Stree" Oration - Orator: Dr. Anne Kihara (President - FIGO)
- FOGSI BOGS Prof. Baidyanath Chakravorty Memorial Oration - Orator: Dr. Rohana Haththotuwa (Secretary General - AOFOG)
- FOGSI RALLIS Oration - Orator: Dr. Hrishikesh Pai (Trustee - FIGO Asia Oceania)
- ICOG Convocation
- Paid Banquet & Cultural Night with Celebrities, Stars & India's Top Singers - Promoting PREVENTION OF CERVICAL CANCER

12

January, 2025

- FOGSI MSD Oration - Orator: Dr. Jaydeep Tank (President - FOGSI, 2024)
- Dr. Kamini Rao Yuva Orations
- FOGSI Prize Winning Talks
- Valedictory Function

SCAN THE QR CODE  
TO REGISTER NOW!



[www.aicogmumbai2025.com](http://www.aicogmumbai2025.com)

Dr. Nandita Palshetkar  
Organizing Chairperson

Dr. Hrishikesh Pai  
Chairperson, Scientific Committee

Dr. Niranjana Chavan  
Organizing Secretary

